

# Location of the contrast extravasation is important in predicting outcome of anterior circulation stroke patients

\*<sup>1</sup>Hüseyin Neziğ Özdemir MD, \*<sup>2</sup>Bedriye Karaman MD, <sup>2</sup>Ayşe Güler MD, <sup>2</sup>Birgöl Dere MD, <sup>3</sup>Celal Çınar MD, <sup>2</sup>Dursun Emre Kumral MD, <sup>2</sup>Hadiye Şirin MD, <sup>2</sup>Neşe Çelebisoy MD  
\*HN Özdemir and B Karaman contributed equally to this work and are co-first authors

<sup>1</sup>Necip Fazıl City Hospital, Department of Neurology, Kahramanmaraş, Turkey; <sup>2</sup>Ege University Medical School, Department of Neurology, İzmir, Turkey; <sup>3</sup>Ege University Medical School, Department of Radiology, İzmir, Turkey

## Abstract

**Objectives:** Contrast extravasations (CE) are frequently seen on postprocedural computed tomography after endovascular therapy (EVT). This study aimed to investigate the relationship between patients' outcomes and CE after EVT. **Methods:** Stroke patients who had received EVT between 2019 and 2021 were reviewed retrospectively. The CEs were mapped using MRICroGL software. The rate of in-hospital mortality and modified Rankin Scale at 90 days were taken as outcome measures. Stepwise logistic regression analyses were performed. Three models were created with and without pure CE to predict the patients' outcomes. **Results:** There were 126 patients included in the study. According to the univariable analysis, CE (OR = 0.70, 95% CI = 0.18–2.68, P = 0.26) and CE-ASPECTS (OR = 1.21, 95% CI=0.60-2.44, P = 0.57) were not related with in-hospital mortality after EVT. The lesion mapping showed that the most common CE locations among the patients with a poor prognosis was the M6 area. The multivariable logistic regression analysis showed that CE in the M6 area (OR = 6.87, 95% CI = 1.27–144.92, P = 0.006) increased the risk of a 3-month poor outcome. The study showed that adding CE to the well-known risk factors for poor prognosis improves the predictive power of the models ( $\Delta$ AUC of 0.07, P = 0.02).

**Conclusion:** CE has a prognostic value after EVT in anterior stroke patients. The prognostic value is the highest when present in the M6 area.

**Keywords:** Stroke, endovascular therapy, contrast extravasation, prognosis

## INTRODUCTION

Stroke is one of the leading causes of mortality and disability worldwide.<sup>1</sup> Endovascular therapy (EVT) has emerged as a robust therapeutic option to treat disabling stroke and is now considered standard treatment for acute stroke patients with large artery occlusion.<sup>2,3</sup> Contrast extravasation (CE) is frequently seen on postprocedural computed tomography after EVT.<sup>4</sup> Blood-brain barrier disruption causes CE.<sup>5,6</sup> Although some studies did not find prognostic value in CE after EVT, most indicated that CE can predict poor prognosis.<sup>7-18</sup> These studies primarily focused on the existence or absence of CE.<sup>7-15</sup> A few recent retrospective studies have suggested that CE in certain locations and high contrast extravasation of the Alberta Stroke Program Early CT score

(CE-ASPECTS) can predict poor prognosis.<sup>16,18</sup> Further investigation is needed to determine the exact CE locations and CE-ASPECTS to predict patient prognosis.

In this study, we aimed to investigate the correlation between postprocedural CE locations and the clinical outcome of anterior circulation patients considering CE-ASPECTS. We used mapping techniques to identify the cerebral areas involved with contrast.

## METHODS

### *Patient selection and clinical data*

This is a retrospective study, reviewing stroke patients who had received EVT between January 2019 and January 2021. The inclusion criteria for

Address correspondence to: Ayşe Güler, Ege University Medical School, Department of Neurology, 35100, İzmir, Turkey. Tel: +90 533 817 18 76, E-mail: aguler7576@hotmail.com

Date of Submission: 13 January 2024; Date of Acceptance: 18 February 2024

<https://doi.org/10.54029/2024wcy>

the study were: being aged over 18 years old, presence of occlusion in a large anterior circulation artery(s), having received an EVT within 24 h of onset, having at least 2 non-contrast computed tomography (NCCT) scans in 6 h and 24 h, and monthly follow-up for at least 3 months for the applicable patients. The study excluded patients with posterior circulation strokes, inadequate CT scans, and follow-ups.

The patients' demographic and clinical information, including age, sex, diabetes mellitus (DM), hypertension, atrial fibrillation, prior transient ischemic attack, or stroke history, was obtained from their medical records. The initial National Institutes of Health Stroke Scale (NIHSS) score prior to EVT, the Alberta Stroke Program Early CT score (ASPECTS), onset to reperfusion time, the modified thrombolysis in cerebral infarction (mTICI) revascularization scale category, bridging intravenous thrombolytic therapy, and endovascular procedure were noted. The mTICI category was classified as successful reperfusion (mTICI 2b-3) and unsuccessful reperfusion (mTICI 0-2a).

#### *EVT procedure*

The American Heart Association/American Stroke Association (AHA/ASA) Guidelines and European Stroke Organization (ESO) Guidelines were used to select acute stroke patients for EVT.<sup>2,3</sup> Acute stroke patients meeting the following criteria received EVT: 0–6 h onset; large vessel occlusion (common carotid artery, internal carotid artery, middle cerebral artery M1 and M2 segment); prestroke mRS  $\leq 2$ ; NIHSS score  $\geq 6$ ; and ASPECTS  $\geq 6$ . The DAWN and DEFUSE-3 study criteria were used to select stroke patients admitted after 6–24 h of stroke onset for EVT.<sup>19,20</sup> All intracranial occlusions were treated with modern mechanical thrombectomy devices such as contact aspiration (Sofia aspiration catheter, Microvention, Tustin, California) or a stent retriever (Solitaire FR revascularization device EV3, Irvine, California, USA).

#### *Diagnosis of contrast extravasation*

All patients had undergone at least 2 NCCT scans 6 h and 24 h after EVT. Baseline images were obtained with a 128-slice multidetector CT scanner (Discovery CT 750 HD; GE Medical Systems, Milwaukee, Wis.) and included unenhanced CT (section thickness, 5 mm; tube voltage, 120 kV; tube current, 80 mA; field of view, 320 x 320 mm; matrix, 512 x 512). A

single experienced neuroradiologist who was blinded to the clinical data (C.C.) interpreted the NCCT images individually. CE was defined as a hyperdense lesion with a maximum Hounsfield unit  $>90$ . The hyperdense lesions that disappeared in 24 h were diagnosed as CE, and those that persisted at least 24 h were diagnosed as hemorrhagic transformation. Patients without CE and HT were grouped as “no hyperdense areas”. ASPECT territories were used to define the brain parenchyma areas affected by CE.<sup>21</sup> Parenchyma areas affected by the CE on the postprocedural NCCT were scored in accordance with ASPECTS, and CE-ASPECTS' were calculated.<sup>21</sup> The European Cooperative Acute Stroke Study 2 (ECASS-2) classification was used to categorize the hemorrhagic transformation. Hemorrhagic transformation was divided into HI1, HI2, PH1, and PH2.<sup>22</sup>

#### *Contrast mapping*

The CEs were mapped using MRIcroGL software (<https://www.nitrc.org/projects/mricrogl>). For each normalized individual imaging, SPM12 (<https://www.fil.ion.ucl.ac.uk/spm/software/>) was used with standard parameters applied in the MATLAB environment (2019 version, MathWorks). A single experienced user (H.N.O.) who was blinded to the clinical data drew the CEs manually. To determine the most frequently affected brain areas, the CEs were overlapped. For this analysis, 15 patients who had CE on the right side were flipped onto the left side.

#### *Neurological outcomes*

The rate of in-hospital mortality and modified Rankin Scale (mRS) at three months after the stroke were taken as outcome measures (for short term and for long term, respectively).<sup>23</sup> A neurologist (B.D.) who was blinded to the radiological data evaluated mRS. The good outcome group included functional patients with mRS 0–2, and patients with mRS 3–6 at three months after EVT were classified in the poor outcome group.

#### *Statistical analysis*

All statistical analyses were performed using SPSS version 25.0 (IBM). Categorical variables were compared using the chi-square test or Fisher's exact test as appropriate. Continuous variables with and without normal distribution were compared using the independent sample t

test and Mann-Whitney U test, respectively. The Shapiro-Wilk test was used to test for normal distribution of the data.

To assess the effect of CE on in-hospital mortality and neurological outcome, stepwise logistic regression analysis was performed. We selected variables related to clinical outcomes reported in previous studies for the logistic regression analysis.<sup>7-18</sup> Univariable odds ratios and 95% confidence limits were first calculated, and the variables with  $P < 0.25$  were included in the logistic regression analysis as independent variables. A  $p$  value of  $< 0.05$  was considered statistically significant. The predictive models were compared using receiver operating characteristic (ROC) curve and the area under the ROC curve (AUC).

## RESULTS

A total of 153 patients received EVT in our clinic between January 2019 and January 2021. The study excluded 11 posterior circulation stroke patients, seven with inadequate NCCT scans, and nine with incomplete follow-ups. In total, it

included 126 patients (Figure 1). Table 1 shows the patients' demographic and clinical features.

CE was present in 34 (26.9%) patients, and hemorrhagic transformation was present in 37 (27.7%) patients. Fifty-seven (45.3%) patients showed no hyperdensity on NCCT scan after EVT. The mean onset to puncture time and the mean onset to reperfusion time were significantly shorter in the no hyperdense areas subgroup than in the CE and hemorrhagic transformation patients ( $P = 0.008$  and  $P < 0.001$ , respectively). Compared to the no hyperdense areas subgroup, internal carotid artery (ICA) stenting was performed more frequently in the CE and hemorrhagic transformation groups (28.5% vs. 47.1% vs. 54.2%, respectively,  $P = 0.01$ ). There was no significant difference in terms of the mean age, sex, vascular risk factors, NIHSS score at presentation, major vessel occlusion localization, baseline ASPECTS, or revascularization score among the three subgroups (Table 1).

The rate of in-hospital mortality was 11.9% (15 of 126 patients) after EVT. According to the univariable analysis, CE in any cerebral location ( $P > 0.05$ ) and CE-ASPECTS (OR=1.21,

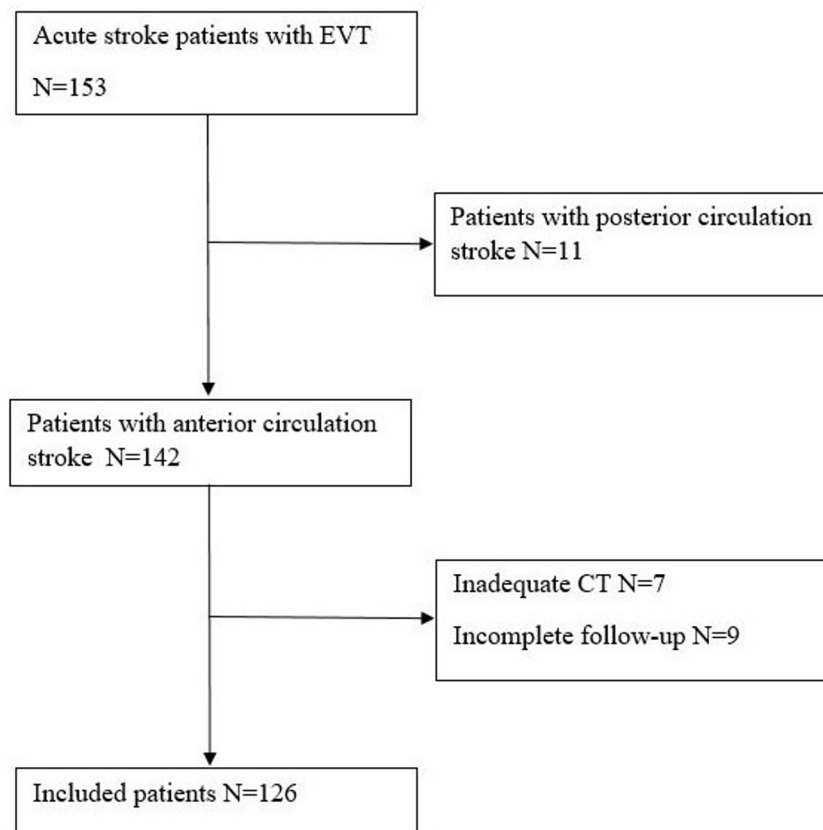


Figure 1. Flowchart of the participant selection.

**Table 1: Demographic and clinical parameters of the patients**

	No Hyperdense Area <i>n</i> =57	Pure Contrast Extravasation <i>n</i> =34	Hemorrhagic Transformation <i>n</i> =35	<i>P</i> value
Age, year, mean (SD)	62.49 (13.75)	67.13 (13.44)	64.84 (11.87)	0.27
Age, > 65 years, <i>n</i> (%)	28 (49.1)	24 (70.5)	20 (57.1)	0.14
Male, <i>n</i> (%)	24 (42.1)	17 (50)	21 (60)	0.25
Type 2 DM, <i>n</i> (%)	20 (35.1)	12 (35.2)	9 (25.7)	0.61
Hypertension, <i>n</i> (%)	36 (63.1)	21 (61.7)	14 (40)	0.07
Coronary Artery Disease, <i>n</i> (%)	12 (21.1)	11 (32.3)	11 (31.4)	0.40
Prior TIA or Stroke, <i>n</i> (%)	5 (8.8)	9 (26.4)	5 (14.2)	0.07
Smoking, <i>n</i> (%)	6 (10.5)	2 (5.8)	2 (5.7)	0.76
Alcohol Consumption, <i>n</i> (%)	2 (3.5)	2 (5.8)	0	0.38
Stroke Cause, <i>n</i> (%)				
Large Artery Atherosclerosis	29 (50.9)	14 (41.1)	16 (45.7)	0.66
Cardioembolic Stroke	28 (49.1)	20 (58.9)	19 (54.3)	
Occlusion Site, <i>n</i> (%)				
Carotid T or L occlusion	11 (19.3)	8 (23.5)	9 (25.7)	0.14
Isolated ICA	0	0	2 (5.7)	
MCA M1	45 (78.9)	23 (67.6)	24 (68.6)	
MCA M2	1 (1.7)	3 (8.8)	0	
OPT, minutes, median (min, max)	101 (13, 590)	152 (64, 755)	131 (26, 1980)	<b>0.008</b>
ORT, minutes, median (min, max)	151 (54, 623)	236 (115, 801)	213 (80, 600)	<b>&lt;0.001</b>
Initial NIHSS Score, median (min, max)	14 (6, 19)	13 (6, 18)	12 (6, 20)	0.82
Baseline ASPECTS median (min, max)	10 (7, 10)	9 (7, 10)	9 (6, 10)	0.27
Intravenous Thrombolysis, <i>n</i> (%)	0	1 (2.9)	2 (5.7)	0.16
Stent Retriever Passes >2, <i>n</i> (%)	7 (12.2)	5 (14.7)	8 (22.8)	0.42
mTICI 2b or 3, <i>n</i> (%)	56 (98.2)	30 (88.2)	32 (91.4)	0.09
ICA Stenting, <i>n</i> (%)	15 (28.1)	16 (47.1)	19 (54.2)	<b>0.01</b>
CE-ASPECTS				
0-4	-	2	-	-
5-7		12		
8-9		20		
Bleeding Classification, <i>n</i> (%)				
HI1	-	-	6 (17.1)	-
HI2			7 (20)	
PH1			6 (17.1)	
PH2			16 (45.8)	

ASPECTS: The Alberta stroke programme early CT score, CE: contrast extravasation, DM: diabetes mellitus, ICA: internal carotid artery, MCA: middle cerebral artery, mTICI: The modified treatment in cerebral infarction, NIHSS: The National Institutes of Health Stroke Scale, OPT: onset to reperfusion time, ORT: onset to reperfusion time, TIA: transient ischemic attack

95% CI=0.60-2.44, *P*=0.57) were not related to in-hospital mortality after EVT; therefore, they were not included in the multivariable analysis (Table 2). According to the multivariable analysis, hemorrhagic transformation (OR=12.13, 95% CI=1.56-94.33, *P*=0.01) and type 2 DM (OR=9.37, 95% CI=1.05-83.17, *P*=0.04) increased the risk of in-hospital mortality. A high baseline ASPECTS reduced the risk of in-hospital

mortality (OR=0.26, 95% CI=0.07-0.91, *P*=0.03). The logistic regression model was significant (*P*<0.001) and correctly predicted 93.7% of the cases (Table 3).

The lesion mapping showed that the most common CE locations among the patients with a poor prognosis were the M6 area (8/16), the M5 area (7/16), and the M4 area (7/16). In contrast, the lentiform nucleus (6/18), caudate (4/18),

**Table 2: Univariable analyses of the contrast locations and CE-ASPECT score for predicting in-hospital mortality and a poor outcome**

	In-hospital Mortality		Poor Outcome	
	Odds Ratio (95% CI)	P-value	Odds Ratio (95% CI)	P-value
CE-ASPECTS	1.21 (0.60- 2.44)	0.57	<b>0.63 (0.42- 0.94)</b>	<b>0.02</b>
CE Locations				
Caudate	0.001 (0.001- 999)	0.99	0.001 (0.001- 999)	0.99
Lentiform Nucleus	0.58 ( 0.71- 4.88)	0.62	0.87 (0.25- 3.03)	0.84
Internal Capsule	0.001 (0.001- 999)	0.99	0.66 (0.06- 6.53)	0.72
Insular Cortex	0.001 (0.001- 999)	0.99	0.69 (0.05- 6.49)	0.70
M1	2.57 (0.25- 26.44)	0.42	0.001 (0.001- 999)	0.99
M2	1.91 (0.19- 18.32)	0.57	0.001 (0.001- 999)	0.99
M3	1.51 (0.16- 13.91)	0.71	1.0 (0.88- 11.35)	1.0
M4	2.69 (0.49- 14.75)	0.26	<b>16.6 (1.96- 139.99)</b>	<b>0.01</b>
M5	0.81 (0.09- 6.88)	0.84	<b>5.40 (1.31- 22.10)</b>	<b>0.01</b>
M6	0.92 (0.10- 7.91)	0.93	<b>19.52 (2.35- 162.18)</b>	<b>0.006</b>

ASPECT: The Alberta stroke programme early CT score, CE: contrast extravasatio, CI: confidence interval

**Table 3: Logistic regression analysis for in-hospital mortality among the acute stroke patients after endovascular treatment**

	Univariable Analysis		Multivariable Analysis	
	Odds Ratio (95% CI)	P-value	Odds Ratio (95% CI)	P-value
Sex (Male)	2.11 (0.67- 6.57)	0.19	2.95 (0.50- 17.43)	0.22
Age (> 65 years)	2.25 (0.67- 7.51)	0.18	1.77 (0.33- 9.47)	0.50
<b>Type 2 DM</b>	7.77 (2.29- 26.34)	0.001	9.37 (1.05- 83.17)	<b>0.04</b>
Hypertension	1.18 (0.39- 3.55)	0.76	NA	NA
Coronary Artery Disease	5.16 (1.67- 15.89)	0.004	3.27 (0.66- 16.14)	0.14
Prior TIA or Stroke	2.71 (0.33- 21.92)	0.35	NA	NA
Smoking	0.81 (0.09- 6.88)	0.84	NA	NA
Alcohol Consumption	0.99 (0.99- 1.01)	0.99	NA	NA
Cardioembolic Stroke	0.39 (0.12- 1.23)	0.10	0.18 (0.03- 1.17)	0.07
MCA M1 or M2 occlusion	2.19 (0.46- 10.32)	0.32	NA	NA
Onset to reperfusion time	1.01 (0.99- 1.03)	0.72	NA	NA
Initial NIHSS Score	1.23 (1.02- 1.48)	0.02	1.16 (0.88- 1.53)	0.27
<b>Baseline ASPECTS</b>	0.19 (0.75- 0.49)	0.01	0.26 (0.07- 0.91)	<b>0.03</b>
Intravenous Thrombolysis	0.99 (0.99- 1.01)	0.99	NA	NA
Stent Retriever Passes >2	0.79 (0.16- 3.82)	0.77	NA	NA
mTICI 0, 1 or 2a	2.69 (0.49- 14.75)	0.25	13.77 (0.58- 87.95)	0.10
ICA Stenting	0.34 (0.09- 1.27)	0.11	0.33 (0.03- 3.12)	0.33
<b>Hemorrhagic Transformation</b>	2.36 (0.78- 7.07)	0.12	12.13 (1.56- 94.33)	<b>0.01</b>

ASPECT: The Alberta stroke programme early CT score, DM: diabetes mellitus, ICA: internal carotid artery, MCA: middle cerebral artery, mTICI: The modified treatment in cerebral infarction, NA: not applicable, NIHSS: The National Institutes of Health Stroke Scale, TIA: transient ischemic attack

internal capsule (4/18), and insular cortex (4/18) were the most frequently involved areas among the patients with a good prognosis (Figure 2).

At the follow-up visit three months after EVT, 84 (66.7%) patients had a good outcome, while 42 (33.3%) patients had a poor outcome. According to the univariable analysis, type 2 DM, coronary artery disease, initial NIHSS score, unsuccessful reperfusion, and CE in the M4, M5, and M6 areas were associated with poor outcomes ( $P < 0.05$ ). Table 3 shows the univariable analysis of the CE locations for predicting a poor outcome. Patients with older age, hypertension, and hemorrhagic transformation tended to have a poor prognosis ( $P < 0.25$ ) (Table 4). These parameters were considered possible factors affecting long-term outcomes and were included in the multivariable analysis.

The multivariable logistic regression analysis showed that type 2 DM (OR=3.97, 95% CI=1.35–11.66,  $P=0.01$ ), initial NIHSS score (OR=1.17, 95% CI=1.01–1.36,  $P=0.03$ ), unsuccessful reperfusion (OR=10.74, 95% CI=1.21–75.54,  $P=0.01$ ), hemorrhagic transformation (OR=3.54, 95% CI=1.21–10.36,  $P=0.02$ ), and CE in the M6 area (OR=6.87, 95% CI=1.27–144.92,  $P=0.006$ ) increased the risk of a poor outcome.

Other parameters, including CE in the M4 area (OR=10.89, 95% CI=0.66–79.65,  $P=0.09$ ), CE in the M5 area (OR=0.18, 95% CI=0.01–3.52,  $P=0.25$ ) and CE-ASPECTS (OR=0.98, 95% CI=0.34–2.82,  $P=0.97$ ), were unsuccessful in demonstrating a correlation with poor outcomes (Table 4). The logistic regression model was significant ( $P < 0.001$ ) and correctly predicted 81.7% of the cases.

Three models were created with and without CE to predict the patients' outcomes. Model 1 included well-known risk factors for poor outcomes, including older age, type 2 DM, hypertension, coronary artery disease, initial NIHSS score, baseline ASPECTS, unsuccessful reperfusion, and hemorrhagic transformation. The AUC of Model 1 was 0.77 (95% CI=0.69–0.84). Model 1 was used as the reference model. The presence of CE in any location was added to the variables included in Model 1 to build Model 2. The presence of CE was associated with poor prognosis (OR=3.59, 95% CI=1.23–10.50,  $P=0.01$ ). The AUC of Model 2 was 0.79 (95% CI=0.71–0.86). In Model 3, the location of CE was specified as in the M6 area, in addition to the well-known risk factors employed in Model 1. CE in the M6 area was predictive for poor prognosis (OR=6.87, 95% CI= 1.27–144.92,

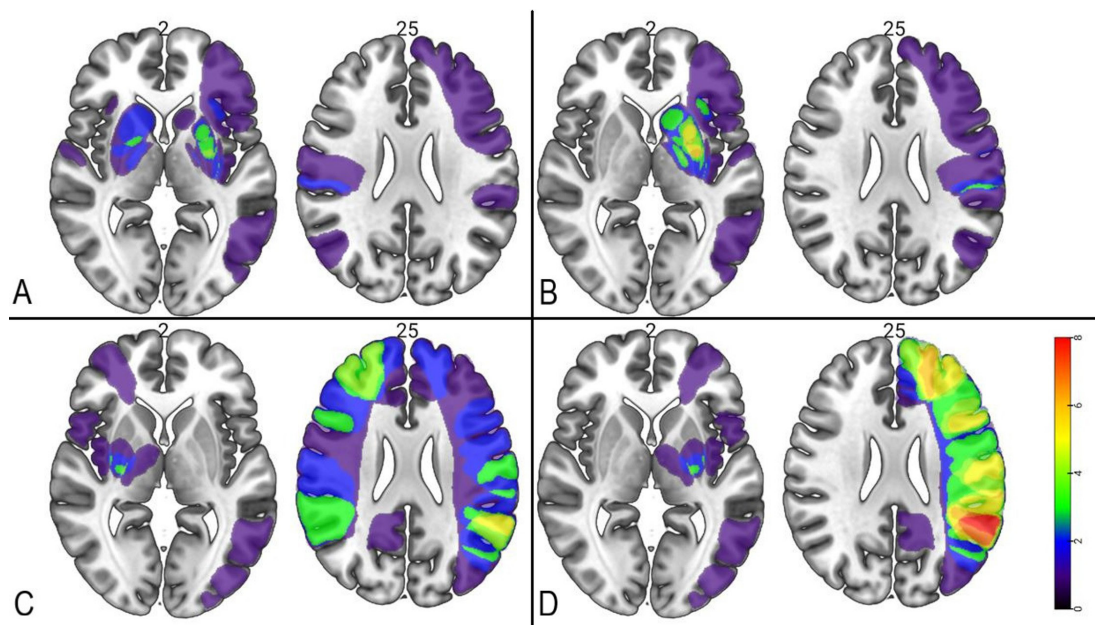


Figure 2. Contrast mapping results of the patients. A- B: CE patients with good prognosis after left-right flip, C-D: CE patients with poor prognosis after left-right flip. The maximum overlap area (8/16) is shown in the M6 territory among the poor prognosis patients after left-right flip. The maximum overlap area is shown in the lentiform nucleus (6/18) among good prognosis patients. The color bar indicates the number of patients who had a lesion in the given voxel.

**Table 4: Logistic regression analysis for a poor outcome among the acute stroke patients after endovascular treatment**

	Univariable Analysis		Multivariable Analysis	
	Odds Ratio (95% CI)	P-value	Odds Ratio (95% CI)	P-value
Sex (Male)	0.78 (0.37- 1.65)	0.52	NA	NA
Age (> 65 years)	1.81 (0.84- 3.93)	0.12	0.98 (0.35- 2.70)	0.97
<b>Type 2 DM</b>	2.47 (1.13- 5.42)	0.02	<b>3.97 (1.35- 11.66)</b>	<b>0.01</b>
Hypertension	1.63 (0.76- 3.50)	0.21	1.45 (0.46- 4.84)	0.51
Coronary Artery Disease	3.80 (1.66- 8.67)	0.002	2.47 (0.88- 6.93)	0.08
Prior TIA or Stroke	1.56 (0.57- 4.23)	0.38	NA	NA
Smoking	1.36 (0.36- 5.13)	0.64	NA	NA
Alcohol Consumption	2.05 (0.27- 15.08)	0.48	NA	NA
Cardioembolic Stroke	1.47 (0.69- 3.11)	0.31	NA	NA
MCA M1 or M2 occlusion	0.99 (0.41- 2.38)	0.99	NA	NA
Onset to reperfusion time	1.01 (0.99- 1.02)	0.76	NA	NA
<b>Initial NIHSS Score</b>	1.15 (1.02- 1.3)	0.01	<b>1.17 (1.01- 1.36)</b>	<b>0.03</b>
Baseline ASPECT Score	0.56 (0.31-1.00)	0.50	0.77 (0.37- 1.61)	0.49
Intravenous Thrombolysis	0.99 (0.88- 11.35)	0.99	NA	NA
Stent Retriever Passes> 2	1.41 (0.52- 3.77)	0.49	NA	NA
<b>mTICI 0, 1 or 2a</b>	6.83 (1.31- 35.49)	0.02	<b>10.74 (1.49- 76.45)</b>	<b>0.01</b>
ICA Stenting	0.74 (0.35- 1.58)	0.44	NA	NA
<b>Hemorrhagic Transformation</b>	1.84 (0.83- 4.08)	0.13	<b>3.56 (1.14- 11.09)</b>	<b>0.02</b>
CE- ASPECTS	0.63 (0.42- 0.94)	0.02	0.98 (0.34- 2.82)	0.97
Contrast Extravasation in the M4 area	16.6 (1.96- 139.99)	0.01	10.69 (0.52- 218.54)	0.12
Contrast Extravasation in the M5 area	5.40 (1.31- 22.10)	0.01	0.17 (0.06- 4.91)	0.25
<b>Contrast Extravasation in the M6 area</b>	19.52 (2.35- 162.18)	0.006	<b>6.87 (1.27- 144.92)</b>	<b>0.006</b>

ASPECT: The Alberta stroke programme early CT score, CE: contrast extravasation, DM: diabetes mellitus, ICA: internal carotid artery, MCA: middle cerebral artery, mTICI: The modified treatment in cerebral infarction, NA: not applicable, NIHSS: The National Institutes of Health Stroke Scale, TIA: transient ischemic attack

P=0.006). The predictive power further improved with an AUC of 0.84 (95% CI=0.76–0.92). We added the CE-ASPECTS to Model 3. The CE-ASPECTS was not associated with poor prognosis (OR=0.98, 95% CI=0.34-2.92, P=0.97) and it did not increase the predictive performance of Model 3. Model 3 was significantly more powerful than Model 1 at predicting patients with poor prognosis ( $\Delta$ AUC of 0.07, P=0.02). Table 4 shows Model 3. Figure 3 shows the ROC curves of the models.

## DISCUSSION

Hyperdense lesions on NCCT are commonly

observed following EVT, and there is ongoing research on the significance of CE.<sup>4</sup> This study found that 69 of 126 patients (54.7%) showed post-EVT hyperdensity, and approximately half of these were considered to have CE. Previous studies have reported a wide range of post-EVT hyperdensities between 30.7% and 84.2%.<sup>7,8</sup> However, one study focused on CE location, and two studies focused on CE-ASPECTS.<sup>16-18</sup>

In the present study, the patients were analyzed in three groups: those with CE, hemorrhagic transformation, and no hyperintensity. The median onset to reperfusion time was significantly shorter in the no-hyperdense areas subgroup than in the

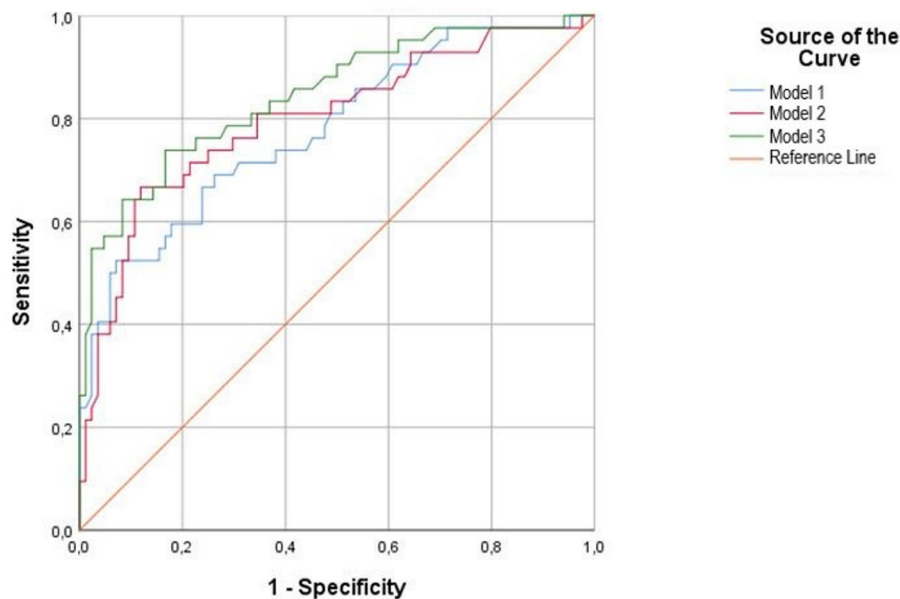


Figure 3. Receiver operator curves of the models

hemorrhagic transformation and CE subgroups ( $P < 0.001$ ). The rate of ICA stenting was also significantly lower in the no hyperdense patients than in the other patients ( $P = 0.01$ ). The primary cause of CE is increased blood-brain barrier permeability due to the susceptibility of hypoxic tissues.<sup>5,6</sup> The longer onset to reperfusion time causes a longer duration of exposure to hypoxia. ICA stenting is associated with reperfusion injury, which contributes to the susceptibility of the tissues.<sup>24,25</sup> Furthermore, ICA stenting takes time and may be one of the reasons for a longer onset to reperfusion time.

The in-hospital mortality rate in this cohort was 11.9%, which is lower than that in a previous study investigating the early mortality rate (22.8%) after EVT in China.<sup>26</sup> The current study did not find a correlation between CE in locations, CE-ASPECTS and in-hospital mortality, in contrast to previous studies.<sup>16-18</sup> Instead of in-hospital mortality, the predictive effect of CE was more evident in long-term prognosis in our study. While hemorrhagic transformation and type 2 DM increased the risk of in-hospital mortality, a high baseline ASPECTS was associated with a lower in-hospital mortality risk in our study. Chen et al. reported that recanalization status, NIHSS score after EVT and symptomatic intracerebral hemorrhage were predictors of early mortality.<sup>26</sup> DM is also associated with in-hospital mortality among stroke patients.<sup>27</sup>

Regarding the long-term outcome, type 2

DM, a high initial NIHSS score, hemorrhagic transformation, and CE in the M6 area were associated with poor prognosis in the current study. Type 2 DM, a high NIHSS score, and hemorrhagic transformation are well-known factors for poor long-term outcomes in stroke patients.<sup>28,29</sup> Studies on the prognostic value of CE have mostly focused on the existence or absence of CE.<sup>7-15</sup> We believe that evaluating the effect of CE based solely on its absence or presence may not provide sufficient distinction. Therefore, we used cerebral mapping techniques to determine the location of CE.

The present study showed that adding CE to the well-known risk factors for poor prognosis improves the predictive power of the models. Considering the ASPECT areas, as in model 3, CE in the M6 area was most clearly associated with poor prognosis. Chang et al. investigated the relationship between the CE volume and localization with poor prognosis in 64 patients with CE who were excluded from hemorrhagic transformation after EVT.<sup>16</sup> Unlike them, we compared the demographic, clinical and imaging characteristics of patients with no hyperdensity, hemorrhagic transformation, or CE after EVT. Then, we assessed the relationship between the CE localizations and prognosis using lesion mapping. Chang *et al.* reported that the caudate nucleus and the M4 and M6 areas were associated with poor prognosis. The two studies found a correlation between decreasing CE-ASPECTS and mRS at the 90th day without specifying a



contrast location.<sup>17,18</sup> In contrast to CE location, the CE-ASPECTS did not affect the predictive power of the multivariable analysis in our study. Therefore, we believe that the prognostic value of CE is highest when present in the M6 area. Although the exact mechanism is unclear, the correlation between CE in cortical areas and poor prognosis may be related to the presence of important functional cerebral areas.<sup>4,16</sup> The other possible explanation is the presence of CE in cortical areas may be related to poor collateral circulation.<sup>16</sup> Previous studies showed that poor collateral circulation is an independent risk factor for poor prognosis after EVT.<sup>30</sup>

The present study had some limitations. Firstly, it had a retrospective design. Patients with insufficient follow-up were excluded, and therefore, the number of patients enrolled decreased. Due to the retrospective design of the study, contrast material doses were not accessible. Although imaging techniques like dual-energy CT, flat-panel CT, and CT-based radiomics nomograms are ideal for differentiating hemorrhagic transformation and CE, we used follow-up conventional NCCT for this purpose due to the facilities of our institute.<sup>31-33</sup> Lastly, the use of dichotomized mRS can cause a decrease in the statistical power.

In conclusion, CE after EVT in anterior circulation stroke patients has prognostic value. It can be helpful in predicting patient outcomes. The prognostic value is the highest when present in the M6 area.

## DISCLOSURE

Ethics: The local ethics committee of the Ege University Medical School approved the study. Ethics committee number: 99166796-050.06.04-1017839/Date: 06.12.2022. Informed consent was obtained from all participants of the study.

Financial support: None

Conflict of interests: None

## REFERENCES

1. Feigin VL, Brainin M, Norrving B, *et al.* World Stroke Organization (WSO): Global stroke fact sheet 2022. *Int J Stroke* 2022; 17:18-29. DOI: 10.1177/17474930211065917.
2. Powers WJ, Rabinstein AA, Ackerson T, *et al.* Guidelines for the early management of patients with acute ischemic stroke: 2019 update to the 2018 Guidelines for the early management of acute ischemic stroke: A guideline for healthcare professionals from the American Heart Association/American Stroke Association. *Stroke* 2019; 50:344-418. DOI: 10.1161/STR.0000000000000211.
3. Turc G, Bhogal P, Fischer U, *et al.* European Stroke Organisation (ESO) - European Society for Minimally Invasive Neurological Therapy (ESMINT) guidelines on mechanical thrombectomy in acute ischemic stroke. *J Neurointerv Surg* 2023; 15(8):e8. DOI: 10.1136/neurintsurg-2018-014569.
4. Xu T, Wang Y, Yuan J, *et al.* Contrast extravasation and outcome of endovascular therapy in acute ischaemic stroke: a systematic review and meta-analysis. *BMJ Open* 2021; 11(7): e044917. DOI: 10.1136/bmjopen-2020-044917.
5. Yang Y, Rosenberg GA. Blood-brain barrier breakdown in acute and chronic cerebrovascular disease. *Stroke* 2011; 42:3323-8. DOI: 10.1161/STROKEAHA.110.608257.
6. Cho HJ, Kim YJ, Lee JH, *et al.* Post-carotid stenting reperfusion injury with blood-brain barrier disruption on gadolinium-enhanced FLAIR MRI. *BMC Neurol* 2014; 14:178-82. DOI: 10.1186/s12883-014-0178-z.
7. Lummel N, Schulte-Altdorneburg G, Bernau C, *et al.* Hyperattenuated intracerebral lesions after mechanical recanalization in acute stroke. *AJNR Am J Neuroradiol* 2014; 35:345-51. DOI: 10.3174/ajnr.A3656.
8. Parrilla G, Garcia-Villalba B, Espinosa de Rueda M, *et al.* Hemorrhage/contrast staining areas after mechanical intra-arterial thrombectomy in acute ischemic stroke: imaging findings and clinical significance. *AJNR Am J Neuroradiol* 2012; 33:1791-6. DOI: 10.3174/ajnr.A3044.
9. An H, Zhao W, Wang J, *et al.* Contrast staining may be associated with intracerebral hemorrhage but not functional outcome in acute ischemic stroke patients treated with endovascular thrombectomy. *Aging Dis* 2019; 10:784-92. DOI: 10.14336/AD.2018.0807.
10. Xu C, Zhou Y, Zhang R, *et al.* Metallic hyperdensity sign on noncontrast CT immediately after mechanical thrombectomy predicts parenchymal hemorrhage in patients with acute large-artery occlusion. *AJNR Am J Neuroradiol* 2019; 40:661-7. DOI: 10.3174/ajnr.A6008.
11. Chen Z, Zhang Y, Su Y, *et al.* Contrast extravasation is predictive of poor clinical outcomes in patients undergoing endovascular therapy for acute ischemic stroke in the anterior circulation. *J Stroke Cerebrovasc Dis* 2020; 29:104494. DOI: 10.1016/j.jstrokecerebrovasdis.2019.104494.
12. Kim JM, Park KY, Lee WJ, *et al.* The cortical contrast accumulation from brain computed tomography after endovascular treatment predicts symptomatic hemorrhage. *Eur J Neurol* 2015; 22:1453-58. DOI: 10.1111/ene.12764.
13. Chen WH, Yi TY, Wu YM, *et al.* Parenchymal hyperdensity on C-arm CT images after endovascular therapy for acute ischaemic stroke predicts a poor prognosis. *Clin Radiol* 2019; 74:399-404. DOI: 10.1016/j.crad.2019.01.009.
14. Portela de Oliveira E, Chakraborty S, Patel M, Finitsis S, Iancu D. Value of high-density sign on CT images after mechanical thrombectomy for large vessel occlusion in predicting hemorrhage and unfavorable

- outcome. *Neuroradiol J* 2021; 34(2):120-7. DOI: 10.1177/1971400920975259.
15. Song SY, Ahn SY, Rhee JJ, *et al.* Extent of contrast enhancement on non-enhanced computed tomography after intra-arterial thrombectomy for acute infarction on anterior circulation: As a predictive value for malignant brain edema. *J Korean Neurosurg Soc* 2015; 58:321-7. DOI: 10.3340/jkns.2015.58.4.321.
  16. Chang GC, Ma DC, Li W, *et al.* Contrast enhancement by location and volume is associated with long-term outcome after thrombectomy in acute ischemic stroke. *Sci Rep* 2022; 12:16998. DOI: 10.1038/s41598-022-21276-3.
  17. Pinckaers FM, Mentink MM, Boogaarts HD, *et al.* Early post-endovascular treatment contrast extravasation on dual-energy CT is associated with clinical and radiological stroke outcomes: A 10-year single-centre experience. *Eur Stroke J* 2023; 8:508-16. DOI: 10.1177/23969873231157901.
  18. Chen L, Xu Z, Zhang C, *et al.* Post-ASPECTS based on hyperdensity in NCCT immediately after thrombectomy is an ultra-early predictor of hemorrhagic transformation and prognosis. *Front Neurol* 2022; 13:887277. DOI: 10.3389/fneur.2022.887277.
  19. Nogueira RG, Jadhav AP, Haussen DC, *et al.* Thrombectomy 6 to 24 hours after stroke with a mismatch between deficit and infarct. *N Engl J Med* 2018; 378:11-21. DOI: 10.1056/NEJMoa1706442.
  20. Albers GW, Marks MP, Kemp S, *et al.* Thrombectomy for stroke at 6 to 16 hours with selection by perfusion imaging. *N Engl J Med* 2018; 378:708-18. DOI: 10.1056/NEJMoa1713973.
  21. Barber PA, Demchuk AM, Zhang J, Buchan AM. Validity and reliability of a quantitative computed tomography score in predicting outcome of hyperacute stroke before thrombolytic therapy. ASPECTS Study Group. Alberta Stroke Programme Early CT Score. *Lancet* 2000; 355(9216):1670-74. DOI: 10.1016/s0140-6736(00)02237-6.
  22. Hacke W, Kaste M, Fieschi C, *et al.* Randomised double-blind placebo-controlled trial of thrombolytic therapy with intravenous alteplase in acute ischaemic stroke (ECASS II). Second European-Australasian Acute Stroke Study Investigators. *Lancet* 1998; 352(9136):1245-51. DOI: 10.1016/s0140-6736(98)08020-9.
  23. Bath PM, Lees KR, Schellinger PD, *et al.* Statistical analysis of the primary outcome in acute stroke trials. *Stroke* 2012; 43(4):1171-78. DOI: 10.1161/STROKEAHA.111.641456.
  24. Cho HJ, Kim YJ, Lee JH, *et al.* Post-carotid stenting reperfusion injury with blood-brain barrier disruption on gadolinium-enhanced FLAIR MRI. *BMC Neurol* 2014; 14:178-82. DOI: 10.1186/s12883-014-0178-z.
  25. Sharma P, Poppe AY, Eesa M, *et al.* Extravasating contrast material on angiography following carotid angioplasty and stenting: not necessarily subarachnoid hemorrhage. *J Neuroimaging* 2010; 20:180-2. DOI: 10.1111/j.1552-6569.2008.00316.x.
  26. Chen Y, Zhou S, Yang S, *et al.* Developing and predicting of early mortality after endovascular thrombectomy in patients with acute ischemic stroke. *Front Neurosci* 2022; 16:1034472. DOI: 10.3389/fnins.2022.1034472.
  27. MacIntosh BJ, Cohen E, Colby-Milley J, *et al.* Diabetes mellitus is associated with poor in-hospital and long-term outcomes in young and midlife stroke survivors. *J Am Heart Assoc* 2021; 10:e019991. DOI: 10.1161/JAHA.120.019991.
  28. Zhang YH, Shi MC, Wang ZX, *et al.* Factors associated with poor outcomes in patients undergoing endovascular therapy for acute ischemic stroke due to large-vessel occlusion in acute anterior circulation: A retrospective study. *World Neurosurg* 2021; 149:128-34. DOI: 10.1016/j.wneu.2021.02.064.
  29. Hong JM, Kim DS, Kim M. Hemorrhagic transformation after ischemic stroke: Mechanisms and management. *Front Neurol* 2021; 12:703258. DOI: 10.3389/fneur.2021.703258.
  30. Seners P, Roca P, Legrand L, *et al.* Better collaterals are independently associated with post-thrombolysis recanalization before thrombectomy. *Stroke* 2019; 50(4):867-72. DOI: 10.1161/STROKEAHA.118.022815.
  31. Renu A, Amaro S, Laredo C, *et al.* Relevance of blood-brain barrier disruption after endovascular treatment of ischemic stroke: dual-energy computed tomographic study. *Stroke* 2015; 46:673-9. DOI: 10.1161/STROKEAHA.114.008147.
  32. Chung Y, Bae Y, Hong CE, *et al.* Hyperattenuations on flat-panel computed tomography after successful recanalization of mechanical thrombectomy for anterior circulation occlusion. *Quant Imaging Med Surg* 2022; 12:1051-62. DOI: 10.21037/qims-21-322.
  33. Ma Y, Wang J, Zhang H, *et al.* A CT-based radiomics nomogram for classification of intraparenchymal hyperdense areas in patients with acute ischemic stroke following mechanical thrombectomy treatment. *Front Neurosci* 2022; 16:1061745. DOI: 10.3389/fnins.2022.1061745.