

Partial Onyx embolization triggers spontaneous regression of cerebral AVM: A case report

Yihui Ma, Zejin Li, Tingbao Zhang, Yu Feng, Wenyuan Zhao

Department of Neurosurgery, Zhongnan Hospital of Wuhan University, Wuhan, China

Abstract

Spontaneous regression of a cerebral arteriovenous malformations (AVMs) is a rare and poorly understood phenomenon. We present a case of unruptured cerebral AVM in a patient presenting with intermittent headache. In order to reduce hemorrhagic risk, the patient underwent partial embolization of the AVM with Onyx glue. Follow-up digital subtraction angiography (DSA) showed complete obliteration of the residual AVM three months after the treatment. In conclusion, partial Onyx embolization of cerebral AVM may be an etiological factor of spontaneous regression. In order to reduce hemorrhagic risk, targeted partial embolization of the AVM may be an alternative treatment for some cases.

Keywords: Cerebral AVM; Onyx embolization; Spontaneous regression

INTRODUCTION

Spontaneous regression of a cerebral arteriovenous malformations (AVMs) is a rare and poorly understood phenomenon. Here we describe a case in which spontaneous regression of a right temporal Spetzler-Martin (SM) grade 2 AVM occurred after partial embolization with Onyx glue.

CASE REPORT

A 55-year-old man presented with a history of intermittent headache for 10 days. There was no history of neck pain, seizures, or any neurological deficit. However, he had a history of claustrophobia and hypertension for many years. Brain computed tomography (CT) revealed abnormal dilated veins in the right temporal lobe suggesting a vascular malformation (Figure 1a). The patient could not undergo magnetic resonance imaging (MRI) due to his claustrophobia. Preoperative digital subtraction angiography (DSA) showed an AVM supplied by the right middle cerebral artery, internal maxillary artery and posterior cerebral artery drained into the superior sagittal sinus (Figure 1b-e). In order to reduce hemorrhagic risk, the patient underwent embolization of the AVM with Onyx glue. We performed partial embolization through branches of the right middle cerebral artery (MCA) using Onyx glue. The immediate postoperative cerebral

angiography showed that the size and flow of the residual AVM significantly reduced (Fig. 1f, g). Unfortunately, the patient developed seizure one week after surgery, and the symptom was effectively controlled after medical treatment. We planned to treat the residual AVM again with intravascular embolization in three months. However, follow-up DSA showed complete obliteration of the residual AVM three months after surgery (Fig. 1 h-k), and confirmed total occlusion of the AVM three months after spontaneous regression (Fig. 1 l-o).

DISCUSSION

Cerebral AVM occurs in approximately 0.14% of the general population, and the most common symptoms are hemorrhage and seizure.^{1,2} The rate of spontaneous regression of cerebral AVM is less than 1% of cerebral AVMs.^{3,4} The phenomenon of partial Onyx embolization triggering spontaneous regression of cerebral AVM is rare. Only one case has been reported in the literature.⁵

At present, the cause of spontaneous regression is still unclear. Some radiological features, such as small AVM size and single draining vein, are related to spontaneous regression.⁶⁻⁸ In a review of literature, Lee *et al.* confirmed that small size and a single draining vein are common radiological features in AVMs with spontaneous regression.⁹ It is reported that intracranial hemorrhage may

Address correspondence to: Wenyuan Zhao, Department of Neurosurgery, Zhongnan Hospital of Wuhan University, Wuhan 430000, China. Email: zhaowenyuan2021@163.com

Date of Submission: 8 June 2022; Date of Acceptance: 1 May 2023

<https://doi.org/10.54029/2023xkw>

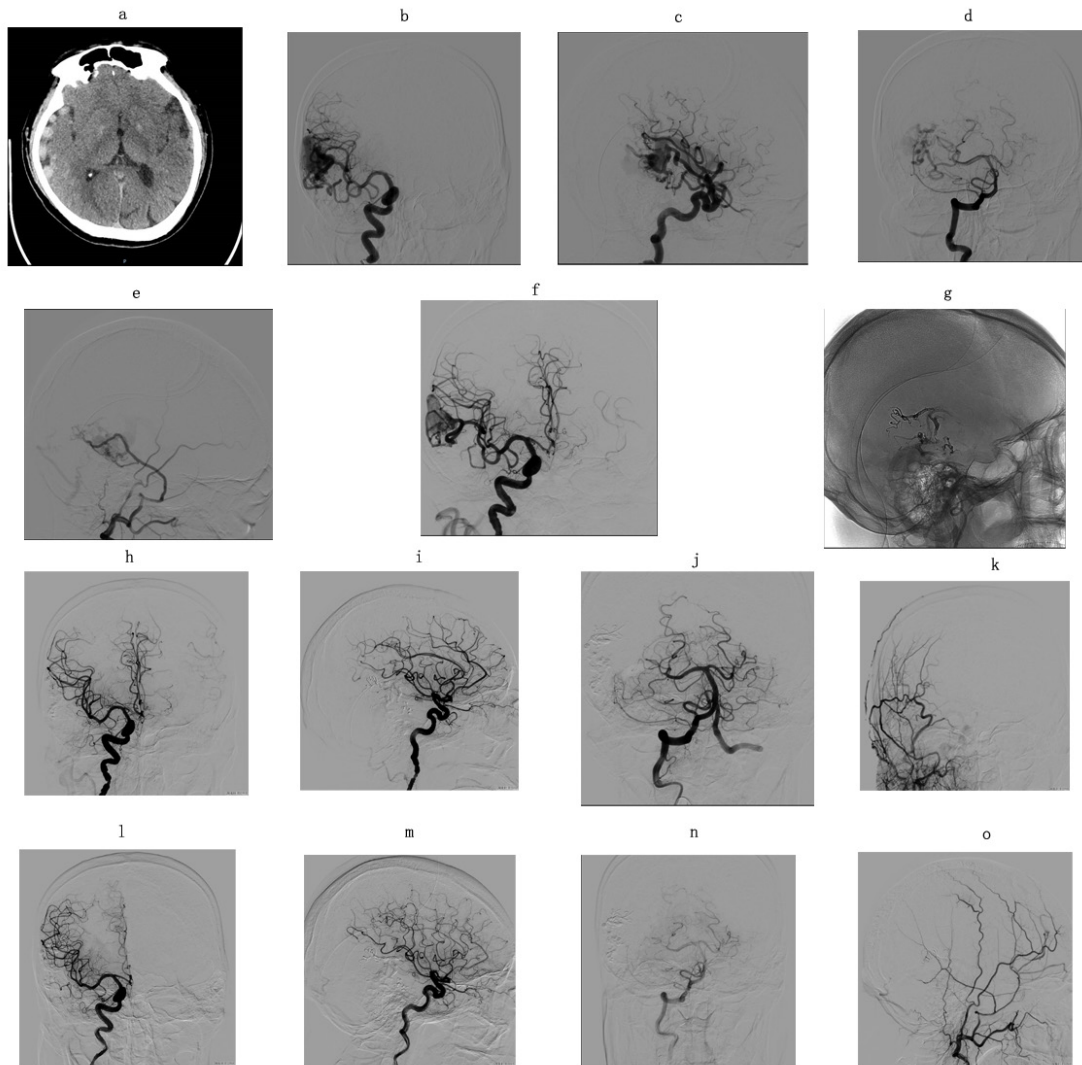


Figure 1. CT demonstrated a hyperdense lesion in the right temporal lobe (a). Pre-operative DSA revealed that the AVM arterial feeders are the right middle cerebral artery, internal maxillary artery, and posterior cerebral artery (b-e). Right internal carotid artery (ICA) angiography showed that the AVM was partially embolized (f, g). Post-operative DSA revealed complete obliteration of the residual AVM three months after surgery (h-k). Follow-up DSA reconfirmed occlusion of the AVM three months after spontaneous regression (l-o).

be an important initial presentation related to spontaneous regression. In contrast, there was no history of intracerebral hematoma in our case. In addition, our patient had multiple arterial feeders and draining veins, including a dominant draining vein without stenosis or aneurysm.

One of the most unanimous hypotheses is the mass effect on the feeding arteries of AVM generated by an intracerebral hematoma and edema, which subsequently leads to thrombosis. Hsu *et al.* reported a case of ruptured cerebral AVM.⁵ The patient underwent emergency

decompressive surgery, and embolization of the AVM with coils and n-butyl cyanoacrylate glue. The residual AVM spontaneously regressed in two months. They assumed that prior parenchymal hemorrhage and neurosurgical intervention rendered the ruptured AVM more susceptible to regression. Furthermore, thrombosis of draining veins may be a more important factor for spontaneous regression. Choi *et al.* reported prominent thrombosis within the vessels by pathologic examination.¹⁰ In our case, the superficial temporal AVM was partially embolized

with Onyx glue. Partial arterial feeders, nidus, and the proximal portion of the dominant draining vein were occluded. Interestingly, spontaneous regression of the AVM occurred three months after surgery, which was reconfirmed by a follow-up angiography another three months later. The thrombosis of the residual arterial feeders, nidus, and draining veins occurred after partial embolization. This finding suggests that partial embolization of cerebral AVM is also an etiological factor of spontaneous regression, which is consistent with the hypothesis by Hsu *et al.*⁵ In order to reduce hemorrhagic risk, targeted partial embolization of the AVM may be an alternative treatment for some cases. Given the risk of bleeding in partially embolized AVM, the selection of patients and types of surgical strategy requires further investigation.

DISCLOSURE

Financial support: This study was supported by the National Natural Science Foundation of China (No. 81401020).

REFERENCES

1. Crowley RW, Ducruet AF, Kalani MY, *et al.* Neurological morbidity and mortality associated with the endovascular treatment of cerebral arteriovenous malformations before and during the onyx era. *J Neurosurg* 2015;122:1492-7. DOI: 10.3171/2015.2.JNS131368
2. Buell TJ, Ding D, Starke RM, *et al.* Embolization-induced angiogenesis in cerebral arteriovenous malformations. *J Clin Neurosci* 2014;21:1866-71. DOI: 10.1016/j.jocn.2014.04.010
3. Buis DR, van den Berg R, Lycklama G, *et al.* Spontaneous regression of brain arteriovenous malformations--a clinical study and a systematic review of the literature. *J Neurol* 2004;251:1375-82. DOI: 10.1007/s00415-004-0548-3
4. Couldwell SM, Kraus KL, Couldwell WT. Regression of cerebral arteriovenous malformation in the puerperium. *Acta Neurochir (Wien)*. 2011;153:359-62. DOI: 10.1007/s00701-010-0897-x
5. Hsu SK, Chang CJ, Su IC. Rendering a ruptured arteriovenous malformation more susceptible to spontaneous obliteration as a possible treatment strategy for cerebral avm. *J Surg Case Rep* 2017;2017:rjx073. DOI: 10.1093/jscr/rjx073
6. Krapf H, Siekmann R, Freudenstein D, *et al.* Spontaneous occlusion of a cerebral arteriovenous malformation: Angiography and mr imaging follow-up and review of the literature. *AJNR Am J Neuroradiol* 2001;22:1556-60. <https://www.ncbi.nlm.nih.gov/pubmed/11559505>
7. Sawlani V, Handique A, Phadke RV. Spontaneous regression of cerebral avm due to thrombosis of draining vein--angiographic and mri demonstration. *J Neurol Sci* 2004;223:195-8. DOI: 10.1016/j.jns.2004.05.003
8. Feldstein E, Riccardello G, Amuluru K, *et al.* Spontaneous regression of cerebral arteriovenous malformation following onyx embolization. *Cureus* 2021;13:e19533. DOI: 10.7759/cureus.19533
9. Lee SK, Vilela P, Willinsky R, *et al.* Spontaneous regression of cerebral arteriovenous malformations: Clinical and angiographic analysis with review of the literature. *Neuroradiology* 2002;44:11-6. DOI: 10.1007/s002340100702
10. Choi JH, Shin JH, Cho SS, *et al.* Spontaneous partial regression of cerebral arteriovenous malformation. *Korean J Radiol* 2002;3:74-7. DOI: 10.3348/kjr.2002.3.1.74