

Rigid spine syndrome in late-onset Pompe disease: A case report and review of the literature

Zhong-Ming Ng, Cheng-Yin Tan, Soon-Chai Low, Nortina Shahrizaila, Khean-Jin Goh

Division of Neurology, Department of Medicine, University of Malaya, Kuala Lumpur, Malaysia

Abstract

Late-onset Pompe disease (LOPD) with rigid spine syndrome (RSS) is a rare phenotype. We report a Chinese man with RSS and mild proximal lower limb weakness since 15 years old. Imaging of paravertebral muscles was normal, while electromyography showed continuous complex repetitive discharges, suggesting paravertebral muscle hyperactivity as a cause of rigidity. Unlike previous reported cases, he carried compound heterozygous *GAA* mutations, including the c.2238G>C, p.Trp746Cys allele, common in Chinese LOPD patients. Combined with two common pseudodeficiency alleles, his genotype predicted a more severe phenotype, as suggested by a very low acid alpha-glucosidase (*GAA*) activity ($<0.1 \mu\text{mol/L/hour}$) on dried blood spot test and a forced vital capacity of 40% of predicted values. Our case demonstrates the absence of genotype-phenotype correlation in LOPD patients with RSS. Continuous muscle hyperactivity could be a reason for spinal rigidity in our patient.

Keywords: Late-onset Pompe disease, rigid spine syndrome, Chinese, acid α -glucosidase, pseudodeficiency

INTRODUCTION

Pompe disease is an inherited autosomal recessive metabolic disorder due to deficiency of acid α -glucosidase (*GAA*), which is a lysosomal enzyme that converts glycogen into glucose, resulting in the accumulation of glycogen in the cardiac, skeletal and smooth muscle, and the nervous system.¹ Pompe disease is classified by the age of onset; infantile-onset Pompe disease (IOPD), presents before the age of one year and is characterized by severe hypotonia, muscle weakness, hepatomegaly and cardiomyopathy.¹ Most infants will die within the first year without treatment. Late-onset Pompe disease (LOPD) presents after the first year of life, in older children, adolescents and adults.^{1,2} Most LOPD patients present with progressive proximal limb and diaphragmatic muscle weakness resulting in a limb-girdle syndrome and respiratory insufficiency while cardiomyopathy is rare.³⁻⁵ Truncal muscle involvement is prominent with weakness of paravertebral and abdominal muscles.⁶ Conversely, spinal rigidity is an unusual LOPD phenotype and often associated with scoliosis and other spinal deformities.²

Rigid spine syndrome (RSS) is a rare clinical myopathy phenotype characterized by limited

movement of the cervical and thoracolumbar spine and attributed to contractures of the axial muscles.⁷⁻⁹ Rigid spine syndrome can be seen in several neuromuscular diseases, including congenital muscular dystrophy (CMD), for example CMD with early spine rigidity (rigid spine muscular dystrophy 1 [RSMD1]) and limb-girdle muscular dystrophies (LGMD) with contractures such as Emery-Dreifuss muscular dystrophy (EDMD).⁷⁻¹⁰

We describe a young man with rigid spine and mild proximal lower limb weakness, who was initially evaluated for possible spinal vertebral disorder with spinal imaging before a myopathic RSS was suspected and later confirmed to have LOPD. Genetic analysis was part of the clinical diagnostic workup and did not require ethics approval. However, informed consent was obtained from the patient for the publication of his clinical information and photographs.

CASE REPORT

A 20-year-old ethnic Chinese man was referred for progressive spinal rigidity and mild proximal lower limb weakness since the age of 15. He noted limitation of neck and back movements in all directions; difficulty in running, climbing stairs

Address correspondence to: Khean-Jin Goh, Division of Neurology, Department of Medicine, University of Malaya, 50603 Kuala Lumpur, MALAYSIA. Tel: +603-79492585, email: gohkj@ummc.edu.my

Date of Submission: 15 March 2021; Date of Acceptance: 24 March 2021

and was unable to perform sit-ups. There was no upper limb weakness, muscle pain or cramps, dysphagia, dyspnea or orthopnea. He is the elder of two children of non-consanguineous parents and there was no family history of neuromuscular disease.

He was generally thin and tall; his height and weight were 172 cm and 41 kg respectively (Figure 1). There was no facial weakness, ophthalmoplegia, ptosis, scapular winging or limb contractures. Upper limb power was Medical Research Council grade 5 in both proximally and distally while lower limbs were grade 4 proximally and grade 5 distally. He had limitation of neck and back flexion and extension but no lordosis or kyphoscoliosis. Gowers sign was negative but Beevor sign was positive. To rise from a supine position, he had to roll on his side before he could sit. Deep tendon reflexes were normal and plantar reflexes were down-going bilaterally. Sensory examinations were normal.

Serum creatine kinase (CK) was raised at 1627 u/L (normal 46-171). Nerve conduction studies were normal but electromyography (EMG) of proximal lower limb muscles suggested myopathic motor unit potentials with early recruitment. Thoracic and lumbar paraspinous muscle EMG showed continuous complex repetitive discharges (CRD). Spinal X-rays showed mild scoliosis and loss of normal spinal curvature while spinal

magnetic resonance imaging (MRI) showed no inflammation or fat infiltration of the paraspinous muscles (Figure 2). Lung function tests showed forced expiratory volume in 1 second (FEV1), forced vital capacity (FVC) and FEV1/FVC ratio of 45%, 40% and 115% of predicted values respectively indicating restrictive pattern. Cardiac echocardiography was normal.

Gene panel screening was negative for *SELENON*, *LMNA*, *EMD*, *CAPN3*, *TOR1AIP1*. Dried blood spot (DBS) test demonstrated very low GAA enzyme activity $<0.1 \mu\text{mol/L/hour}$ (normal > 2.0) and genetic analysis detected two heterozygous mutations in the *GAA* gene, c.2238G>C (p.Trp746Cys) and c.2815_2816del (p.Val939Leufs*78), confirming Pompe disease. He also carried two *GAA* pseudodeficiency alleles; c.1726G>A (p.Gly576Ser) and c.2065G>A (p.Glu689Lys). His parents were carriers of one the *GAA* pathogenic mutations each, while his father also had both pseudodeficiency alleles. His asymptomatic younger sister carried one pathogenic mutation (c.2238G>C) and both pseudodeficiency alleles. The patient declined to undergo muscle biopsy as the diagnosis was already confirmed genetically.

After genetic counselling, the patient was referred for enzyme replacement therapy with intravenous recombinant alglucosidase alfa.

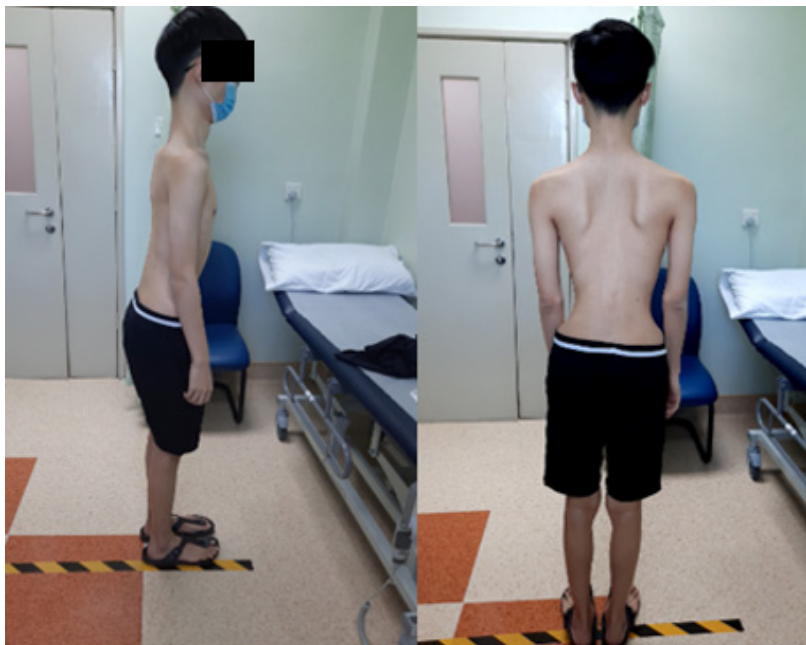

Figure 1: The patient with rigid spine and thin body-built, with loss of normal spinal curvature and minimal scoliosis.

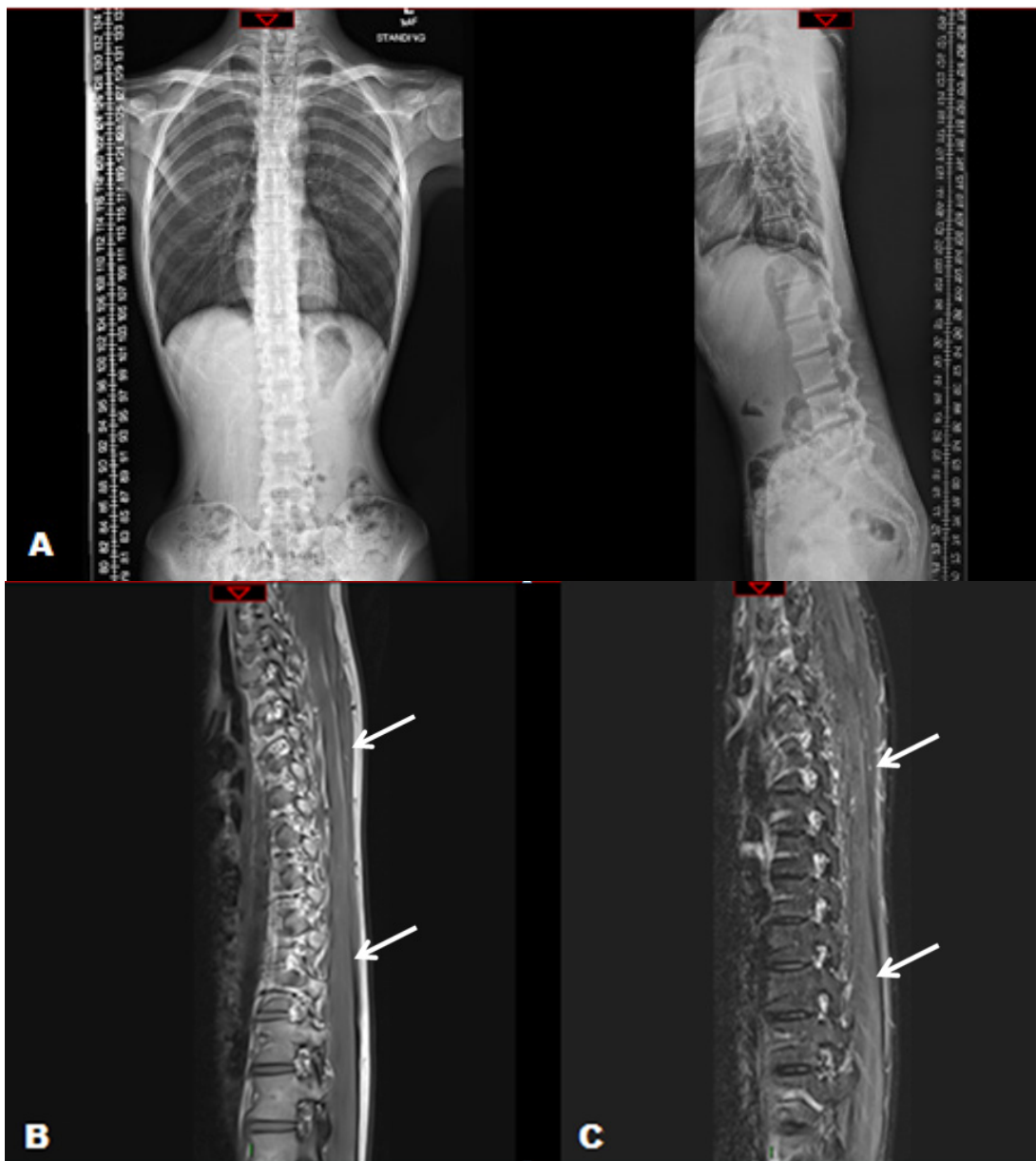


Figure 2: Anterior-Posterior (AP) and lateral X-ray of the spine (A) showing a straight spine with only minimal scoliosis and no kyphosis or lordosis. MRI sagittal view of the thoracolumbar spine (B) T1-weighted and (C) Short Tau Inversion Recovery (STIR) sequences showed relatively preserved paravertebral muscles (white arrows) without fat infiltration or inflammation.

DISCUSSION

Our patient is the first reported Chinese LOPD patient with RSS, a rare phenotype.^{2,11-14} (Table 1). Similar to our patient, previous reported cases presented in adolescence, but unlike our patient, had additional significant spinal deformities including scoliosis and kypho-lordosis.¹¹⁻¹⁴ Prominent features were a thin body-built with low body mass index (BMI), reduced

muscle bulk and axial muscle much weaker than limb muscles.¹¹⁻¹³ The BMI of our patient was 13.9 kg/m² (normal 18.5-24.9). Low BMI was also highlighted in a series of 44 German patients with LOPD, 7 (16%) patients, who presented with rigid spine, scoliosis, low BMI with axial muscles weakness.² RSS was also found in one (3.3%) patient from a cohort of 30 LOPD Italian patients and one (10%) in 10 Polish LOPD patients detected by screening 337 patients using

Table 1: Case series and reports of late onset Pompe disease patients with rigid spine syndrome in the literature

Source	Number of patients (%)	Age of onset	LGMW	Spinal deformity	Paraspinal EMG	Spine imaging	RFT	Gene mutation
Schüller <i>et al.</i> ²	7/44 (16%)	12-20 years	Present	Scoliosis and lumbar hyperlordosis	Not reported	Not reported	Respiratory insufficiency	Common IVS splice site mutation (c.-32-13T > G) in one allele
Jastrzębska <i>et al.</i> ⁶	1/10 (10%)	Since childhood	Present	Not reported	Not reported	Not reported	Restrictive	c.-32-13T > G in one allele
Müller-Felber <i>et al.</i> ³	1/38 (2.6%)	15 years	Present	Not reported	Not reported	Not reported	Required ventilation	c.45T >G / L355P (c.1064T > C)
Montagnese <i>et al.</i> ¹⁵	1/30 (3.3%)	Not reported	Not reported	Not reported	Not reported	Not reported	Not reported	Not reported
Fadic <i>et al.</i> ¹¹	Single case	16 years	Present	Thoracolumbar Scoliosis	Myotonia and CRD	Not reported	FVC 58% predicted	Not reported
Kostera-Pruszyk <i>et al.</i> ¹²	Single case	12 years	Present	Thoracolumbar scoliosis	Not reported	Not reported	FVC 19% predicted (restrictive)	IVS1 (13T>G)/ E888X
Laforêt <i>et al.</i> ¹³	Single case	15 years	Present	Scoliosis	Pseudo myotonia	CT: Severe atrophy with fat replacement of thoracic and lumbar paraspinal muscles	FVC 96% sitting and 86% supine	c.525delT / c.517_519delATG
Panosyan <i>et al.</i> ¹⁴	Single case	14 years	None	Kyphosis and lumbar hyperlordosis	Myotonia and CRD	MRI: Severe atrophy with fat infiltration of dorsal and lumbar musculature	FVC reduced to 2.72 L and worsened by 40% supine	Two <i>GAA</i> gene mutations found
Current study	Single case	15 years	Present	None	CRD	MRI: normal	FVC 40% predicted, restrictive	c.2238G>C/ c.2815_2816del (p.Trp746Cys/ p.Val939Leufs*78)

Abbreviations: CRD: complex repetitive discharges, CT: computed tomography, *GAA*, acid alpha glucosidase, IVS: intervening sequence, EMG: electromyography, FEV1: forced expiratory volume in 1 second, FVC: forced vital capacity, LGMW: limb-girdle muscle weakness, MRI: magnetic resonance imaging, RFT: Respiratory Function Tests

DBS testing.^{15,16} Spinal rigidity in LOPD has not been well-explained. In other myopathic RSS, rigidity has often been attributed to spinal muscle contractures.⁸ However, in LOPD, high frequency EMG discharges such as myotonic and CRD are often seen in the paravertebral muscles.¹⁷ CRD is believed due to ephaptic excitation of adjacent muscle fibers, and we postulate that in early stages of the myopathy, this may result in muscle fiber hyperactivity leading to spinal rigidity.¹⁸ This could be an explanation in our patient, who had normal paravertebral muscles on imaging.

Most European LOPD patients with RSS carried the mild c.-32-13T>G splice site mutation in one of their alleles.^{2,12,15,16} This is a common mutation among Caucasians and has a broad spectrum of phenotypes, substantially influenced by secondary modifying factors.^{2,19} Our patient carried c.2238G>C (p.Trp746Cys) mutation in one allele, previously identified as a common mutation in Chinese LOPD patients from China (27.1% of alleles), Taiwan (37.5% of alleles) and Hong Kong.^{5,20,21} However, none of the previous LOPD cases reported in ethnic Chinese had RSS. Chinese LOPD patients have an earlier symptom-onset (median age of 15 years) and more rapid disease progression.^{5,20} The more severe course was explained by the combination of pathogenic alleles including the c.2238G>C (p.Trp746Cys) with pseudodeficiency alleles viz. c.1726 G>E (p.Gly576Ser) and c.2065G>A (p.Glu689Lys), which are commonly found in the Chinese population.²⁰ While patients with RSS phenotype have been reported with slow disease progression; in one case report, the patient was diagnosed at the age of 71. Our patient had both these pseudodeficiency alleles and very low enzyme activity suggesting the risk of a more rapid and progressive disease.¹⁴ Although he currently has mild limb weakness, lung function tests (FVC and FEV1) have already shown about 60% reduction from predicted values. Hence despite the cost, he should be considered for enzyme replacement therapy as soon as possible.

Our patient was detected as part of routine screening of LOPD in patients who present with limb-girdle weakness and hyperCKemia. Although our patient also had both these clinical features, this report suggests that RSS is another important clinical phenotype and should be screened for LOPD.

In conclusion, to the best of our knowledge, this is the first case of a Chinese LOPD patient with RSS. Unlike previous Caucasian cases, he carried a common Chinese LOPD allele and

two pseudodeficiency alleles, indicating a lack of genotype-phenotype correlation for LOPD with RSS. The relatively normal spinal imaging suggests continuous muscle hyperactivity as the reason for spinal rigidity. RSS should be an important additional clinical feature to screening for LOPD.

ACKNOWLEDGEMENTS

The authors thank the patient and his family for their cooperation and permission to publish this work and his photographs. We also thank Sanofi-Genzyme for their sponsorship of DBS and GAA gene tests for the patient.

DISCLOSURE

Financial support: K J Goh received funds from Sanofi Genzyme (Malaysia) for sponsorship of DBS and GAA gene testing.

Conflict of interest: None

REFERENCES

1. Dasouki M, Jawdat O, Almadhoun O, *et al.* Pompe disease: Literature review and case series. *Neurol Clin* 2014;32:751-76.
2. Schüller A, Wenninger S, Strigl-Pill N, Schoser B. Toward deconstructing the phenotype of late-onset Pompe disease. *Am J Med Genet Part C Semin Med Genet* 2012;160C:80-8
3. Müller-Felber W, Horvath R, Gempel K, *et al.* Late onset Pompe disease: clinical and neurophysiological spectrum of 38 patients including long-term follow-up in 18 patients. *Neuromuscul Disord* 2007;17:698-706.
4. Hagemans MLC, Winkel LPF, Van Doorn PA, *et al.* Clinical manifestation and natural course of late-onset Pompe's disease in 54 Dutch patients. *Brain* 2005;128:671-7.
5. Chu YP, Sheng B, Lau KK, *et al.* Clinical manifestation of late onset Pompe disease patients in Hong Kong. *Neuromuscul Disord* 2016; 26:873-87.
6. Alejaldre A, Díaz-Manera J, Ravaglia S, *et al.* Trunk muscle involvement in late-onset Pompe disease: Study of thirty patients. *Neuromuscul Disord* 2012;22 (Suppl 2):S148-S154.
7. Dubowitz V. Rigid spine syndrome: a muscle syndrome in search of a name. *Proc R Soc Med* 1973;66:219-20.
8. Merlini L, Granata C, Ballestrazzi A, Marini ML. Rigid spine syndrome and rigid spine sign in myopathies. *J Child Neurol* 1989;4:274-82.
9. Moghadaszadeh B, Topaloglu H, Merlini L, *et al.* Genetic heterogeneity of congenital muscular dystrophy with rigid spine syndrome. *Neuromuscul Disord* 1999;9:376-82.
10. Kubo S, Tsukahara T, Takemitsu M, *et al.* Presence of emerinopathy in cases of rigid spine syndrome. *Neuromuscul Disord* 1998;8:502-7

11. Fadic R, Waclawik AJ, Brooks BR, Lotz BP. The rigid spine syndrome due to acid maltase deficiency. *Muscle Nerve* 1997;20:364-6
12. Kostera-Pruszczyk A, Opuchlik A, Lugowska A, *et al.* Juvenile onset acid maltase deficiency presenting as a rigid spine syndrome. *Neuromuscul Disord* 2006;16:282-5.
13. Laforêt P, Doppler V, Caillaud C, Laloui K, *et al.* Rigid spine syndrome revealing late-onset Pompe disease. *Neuromuscul Disord* 2010;20:128-30.
14. Panosyan FB, Fitzpatrick MF, Bolton CF. Late onset Pompe disease mimicking rigid spine syndrome. *Can J Neurol Sci* 2014;41:286-9.
15. Montagnese F, Barca E, Musumeci O, *et al.* Clinical and molecular aspects of 30 patients with late-onset Pompe disease (LOPD): unusual features and response to treatment. *J Neurol* 2015;262:968-78.
16. Jastrzębska A, Potulska-Chromik A, Łusakowska A, *et al.* Screening for late-onset Pompe disease in Poland. *Acta Neurol Scand* 2019;140:239-43
17. Kassardjian CD, Engel AG, Sorenson EJ. Electromyographic findings in 37 patients with adult-onset acid maltase deficiency. *Muscle Nerve* 2015;51:759-61.
18. Hanisch F, Kronenberger C, Zierz S, Kornhuber M. The significance of pathological spontaneous activity in various myopathies. *Clin Neurophysiol* 2014; 125: 1485-90.
19. Kroos MA, Pomponio RJ, Hagemans, *et al.* Broad spectrum of Pompe disease in patients with the same c.-32-13T->G haplotype. *Neurology* 2007;68:110-5.
20. Liu X, Wang Z, Jin W, *et al.* Clinical and GAA gene mutation analysis in mainland Chinese patients with late-onset Pompe disease: identifying c.2238G > C as the most common mutation. *BMC Med Genet* 2014;15:141.
21. Yang CC, Chien YH, Lee NC, *et al.* Rapid progressive course of later-onset Pompe disease in Chinese patients. *Mol Genet Metab* 2011;104:284-8.