

Strokes due to vertebral and carotid artery dissections, a comparative study

¹Jaifrin Daniel MBBS, ²Sanjith Aaron DM Neurology, ¹Thambu David Sudarsanam MD Internal Medicine, ¹Angel Miraclin MD Internal Medicine, ³Harshad Arvind Vanjare MD Radiology, ⁴Bijesh Yadav MSC Biostatistics

¹Departments of Internal Medicine, ²Neurology, ³Radiology, ⁴Biostatistics, Christian Medical College Hospital, Vellore, Tamilnadu, India

Abstract

Background and Objective: Arterial dissection is an important etiology of stroke in the young. This study was done to compare the risk factors and long-term outcomes following stroke due to vertebral and carotid artery dissections. **Methods:** A retrospective cohort study was conducted. The data was collected through the electronic medical record and they were followed up at discharge, at 3 months and 6 months after the stroke. **Result:** The study period was between 01/01/2011 to 01/01/2018. There were 4,131 cases of strokes, among which 1,756 (42.5%) were ischemic strokes. Among the ischemic stroke 39 (2.2 %) were due to dissection. The mean age was 30.68 (12.2) years and 36.42 (10.15) years among vertebral artery dissection (VAD) and carotid artery dissection (CAD) respectively. There was male preponderance (87.2%) in both groups. Trauma was the most common predisposing factor seen among 38.9 % and 38.1% of the VAD and CAD respectively while headache and neck pain were the common initial symptoms. Multimodal imaging technique was needed to confirm the diagnosis of dissection in > 50%. The VAD cohort appears to have a better outcome with 57.3% achieving a modified Rankin Score of ≤ 2 at 6 months compared with only 29.4% in the CAD cohort.

Conclusion: The clinical presentation and etiology were similar in CAD and VAD. In suspected cases of both VAD and CAD multimodal imaging technique may be needed for confirming diagnosis. VAD appears to have better long-term outcome compared to CAD.

Keywords: Carotid artery dissection, modified Rankin Score, vertebral artery dissection

INTRODUCTION

The term dissection implies a tear in the wall of a major artery leading to the intrusion of blood within the layers of an arterial wall (intramural hematoma). There is stenosis of the lumen when blood collects between the intima and media or an aneurysmal dilatation of the artery when the hematoma predominantly involves the media and adventitia.¹

Eighty percent of cranio-cervical dissection is due to internal carotid artery dissection while 15% is contributed by vertebral artery dissection (VAD).^{1,2} In community based studies, the incidence of spontaneous carotid artery dissection (CAD) is 2-3/1,00,000^{3,4} while the incidence is 1-1.5/1,00,000 for spontaneous vertebral artery dissection.^{5,6} The peak incidence of cervical artery dissection is in the fifth decade and they can

occur between 35-50 years.⁵ Overall spontaneous dissections of the carotid and vertebral artery contribute to 2% of all ischemic strokes.^{4,6,7} However dissection is an important cause for strokes in the young contributing to 20% of ischemic strokes in individuals less than 45 years.⁸ Complete imaging of the vessels of the head and neck is required since 15 % of the individuals can have bilateral dissections.^{1,2,9}

The etiopathogenesis of cervical artery dissection is not fully understood. A history of preceding neck trauma is common although not universal. Heritable connective disorders such as Ehlers-Danlos syndrome, Marfan's syndrome, α_1 antitrypsin deficiency etc. may predispose to arterial dissections.

In this study we are comparing the clinical features, etiology and outcome of patients with CAD and VAD.

Address correspondence to: Jaifrin Daniel, Department of Internal Medicine, Unit 2, Christian Medical College Hospital, Vellore - 632004, Tamilnadu, India. Tel: 9789230877, Email: jdaniel.m07@gmail.com

Date of Submission: 7 March 2021; Date of Acceptance: 9 March 2021

METHODS

We did a retrospective observational cohort study. The primary objective of the study was to evaluate and compare the etiological factors, clinical features and outcome of ischemic strokes due to CAD and VAD.

STROBE checklist was used for designing the study and reporting the outcome. The study protocol was approved by the Institutional Review Board Reference No.11276 dated 28/03/2018. The study period was between 01/01/2011 to 01/01/2018.

The inclusion criteria were individuals who had presented with ischemic strokes due to dissections proven by vessel imaging. The baseline characteristic's, risk factors, comorbidities, and examination findings were accessed through the electronic medical records. The Radiological images were accessed via the Picture Archiving and Communication System (PACS). The in-

hospital management, complications and follow up data were accessed via the electronic medical record.

The data was collected using a case report form designed for this study and analysis done with SPSS for windows version 17, IBM Corporation. Statistical analysis was done using a Statistical Package STATA.

RESULTS

During the study period there were 4,131 cases of strokes which were admitted among which 1756 (42.5%) were ischemic strokes while 2375 (57.5%) were hemorrhagic strokes. Among the ischemic stroke 39 (2.2%) were due to dissection (Figure 1). Out of 1,756 cases of ischemic strokes, 331 (18.8%) patients were less than 40 years of age.

There was male preponderance (87.2%) in both groups. (Table 1). Eight (44.4%) of the VAD while 6 (28.6%) of the CAD had presented

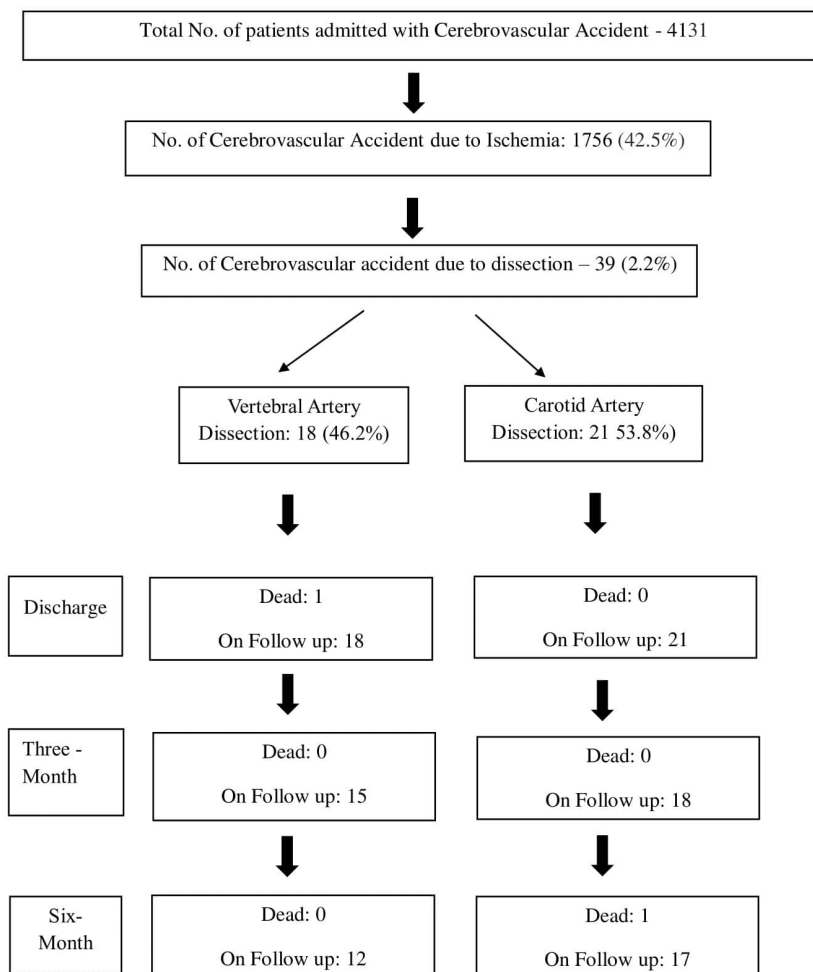


Figure 1: STROBE figure

Table 1: Baseline characteristics of the study subjects

	Vertebral Artery Dissection N=18	Carotid Artery Dissection N=21	p-value
Age Mean –Years (SD)	30.68 (12.2)	36.42 (10.15)	0.12
Male Sex	17 (94.4%)	17 (80.9%)	0.44
Time of onset of symptoms to presentation			
< 6 hours	8 (44.4%)	6 (28.6%)	
6-24 hours	2 (11.1%)	9 (42.8 %)	
24-48 hours	1 (5.5 %)	1 (4.8 %)	
>48 hours	7 (38.9%)	5 (23.8 %)	
</= 24 Hours	10 (55.5%)	15(71.4%)	0.49
>/=24 Hours	8 (44.4%)	6 (28.6%)	
Comorbidities			
Diabetes Mellitus	2 (11.1%)	2 (9.5%)	0.99
Hypertension	0	3 (14.3%)	
Smoking	4 (22.2%)	9 (42.8%)	0.31
Alcohol	5 (27.8%)	9 (42.8%)	0.52
Hyperhomocysteinemia	1 (5.5%)	5 (23.8%)	0.26
Vitamin B 12 Deficiency	1 (5.5%)	3 (14.3%)	0.71
Dyslipidemia	0	1 (4.8%)	NA

within 6 hours of onset of the symptoms. Thus, the time to seek medical help was earlier in the VAD cohort. The CAD individuals had more atherosclerotic risks; however, they did not reach statistical significance (Table 1).

The most common presentation among the VAD was neck pain (77.8%) and vomiting (77.8%) while among the CAD, dysarthria (85.7%, p0.02) and vomiting (61.9%) were the most common presentation (Table 2). Trauma was the most common predisposing factor seen among 38.9 % and 38.1% of the VAD and CAD respectively (Table 3).

Radiological imaging

Multimodal imaging technique was used to diagnose dissection. For diagnosing VAD; MRI brain with MRA and CT angiogram was done for 72% and in the remaining CTA was used. Among CAD, MRI Brain with MRA and CT angiogram was done in 57% and in the remaining 43% a combination of MRI/MRA and carotid Doppler was done for diagnosis (Table 4).

In VAD the arterial segment involved was the isolated V3 segment in 11 (61.1%), followed by a combination of V3 and V4 segments in 3 (16.7%) and a combination of V2 and V3 segments in 2 (11.1%). One patient had isolated V1 Segment dissection and another had a dissection involving all the 4 segments.

In 17 (80.9%) of the CADs the extracranial arterial segment was involved, and in 3 (14.3%) there was extracranial segment involvement with intracranial extension. One patient (4.8%) had isolated intracranial dissection.

Infarcts due to VAD was seen involving the cerebellar hemispheres in 95% along with involvement of the medulla and in 2 (11.1%) there was infarcts in the pons. In one there was involvement of the spinal cord (Opalski syndrome). Malignant MCA infarcts due to CAD was seen in 5 (23.8%) and in 4 (19.1%) the CAD had caused watershed infarcts.

One patient each with CAD and VAD had to undergo surgical decompression for malignant MCA and suboccipital decompression for a large

Table 2: Clinical presentation of the study subjects

Clinical Symptoms and signs	Vertebral Artery Dissection N=18	Carotid Artery Dissection N=21	p-value
Headache	11 (61.1%)	9 (42.8%)	0.41
Neck pain	14 (77.8%)	10 (47.6%)	0.11
Vomiting	14 (77.8%)	13 (61.9%)	0.47
Giddiness	13 (72.2%)	9 (42.8%)	0.13
Horner's syndrome	3 (16.7%)	2 (9.5%)	0.85
Dysphagia	13 (72.2%)	12 (57.1%)	0.52
Dysarthria	8 (44.4%)	18 (85.7%)	0.02
Diplopia	5 (27.8%)	1 (4.8%)	0.12

cerebellar infarct. Four of the VAD patients with one CAD patient with a large MCA Infarcts required mechanical ventilation. In those with intraluminal thrombi a combination of anticoagulant and antiplatelet agents was used while other were treated with antiplatelet agents (Table 5).

Outcome

During the hospitalization, hemorrhagic transformation was seen in 1 patient in each group. Among the VAD, the commonest complication seen was dyselectrolytemia (1) and exposure keratitis (1) while amount the CAD it was pressure ulcer (4), deep vein thrombosis (2), and phenytoin toxicity (1).

At follow up among the VAD, recurrent stroke

(1) was seen. Three individuals among the CAD developed post stroke seizure. There were 2 mortality seen in our study cohort, 1 among the VAD during the hospitalization and 1 among the CAD at six months follow up (Table 6). Table 7 lists the modified Rankin Scale (mRS) of the patients and Table 8 the radiology follow up.

DISCUSSION

Our cohort reflected the male predominance similar to what was seen in other series.¹¹⁻¹³ However, in our cohort VAD and CAD appeared to be causing strokes in much younger population. The mean age of VAD cohort was 30.68 (12.2) years while for CAD it was 36.42 (10.15) years, which was significantly less as compared to 43 (9) years and 44.6 (10) years, as seen by Arnold

Table 3: Precipitating factors of the patients

Precipitating factors	Vertebral Artery Dissection N=18	Carotid Artery Dissection N=21
RTA*	3 (16.7%)	7 (33.3%)
Fall from height	1 (5.5%)	0
Stretching	1 (5.5%)	0
Fall from height + atlantoaxial dislocation	1 (5.5%)	0
Bull gore injury	0	1 (4.8%)
Chiropractic maneuver	1 (5.5%)	0
Attempted suicide by hanging	1 (5.5%)	0
Vertebrobasilar dolichoectasia	1 (5.5%)	0
Post-operative	0	1 (4.8%)
No etiology detected	9 (50%)	12 (57.1)

* RTA: Road traffic accident

Table 4: Radiology findings**(A) Vertebral artery dissection**

Radiological parameter's	Vertebral Artery Dissection N=18
Radiological Imaging	
MRI* + MRA† + CTA‡	13 (72.2%)
MRI + MRA + CT§	1 (5.5%)
Doppler	13 (72.2%)
MRI + MRA	1 (5.5%)
Arterial segment involved	
V1	1 (5.5%)
V2, V3	2 (11.1%)
V3	11 (61.1%)
V3, V4	3 (16.7%)
V1-V4	1 (5.5%)
Brain territory involved	
Cerebellum + Medulla	11 (61.1%)
Cerebellum	2 (11.1%)
Cerebellum + Pons	2 (11.1%)
Medulla	1 (5.5%)
Cerebellum + Thalamus	1 (5.5%)
Spinal cord	1 (5.5%)

* MRI: Magnetic Resonance Imaging.

† MRA: Magnetic Resonance Angiography

‡ CTA: Computerized Tomography Angiography.

§ CT: Computed Tomography

(B) Carotid artery dissection

Radiological parameter's	Carotid Artery Dissection N=21
Radiological imaging	
MRI* + MRA† + CTA‡	12 (57.1%)
MRI + MRA + CT§	1 (4.8%)
Doppler	18 (85.7%)
MRI + MRA	1 (4.8%)
Arterial segment involved	
Extracranial	17 (80.9%)
Intracranial	1 (4.8%)
Extra and Intracranial	3 (14.3%)
Brain territory involved	
MCA	8 (38.1%)
Malignant MCA	5 (23.8%)
MCA + Watershed	4 (19.1%)
MCA + ACA¶	2 (9.5%)
Multi-infarct	2 (9.5%)

* MRI: Magnetic Resonance Imaging.

† MRA: Magnetic Resonance Angiography

‡ CTA: Computerized Tomography Angiography.

§ CT: Computed Tomography

| MCA: Middle Cerebral Artery

¶ ACA: Anterior Cerebral Artery

Table 5: In-Hospital management

	Vertebral Artery Dissection N=18	Carotid Artery Dissection N=21
Antiplatelet + anticoagulation	14 (77.8%)	15 (71.4%)
Antiplatelet	2 (11.1%)	5 (23.8%)
Double antiplatelet	2 (11.1%)	1 (4.8%)
Surgical decompression	1 (5.5%)	1 (4.8%)
Mechanical ventilation	4 (22.2%)	1 (4.8%)

et al., and Milhaud *et al.* respectively.^{10,11}

We found that warning signs of headache and neck pain was present in higher proportion in VAD and also these VAD patients sought medical help earlier (44.4%) of the VAD Patients presented within 6 hours of onset of symptoms as compared to (28.6%) of CAD patients. The proportion of individuals with comorbidities like diabetes mellitus and hypertension was low in our cohort which is similar to as seen by Arnold *et al* and Milhaud *et al.*^{10,11} There was higher proportion of individuals (9, 42.8%) who smoked in the CAD cohort as compared to 27% as seen by Milhaud *et al.*¹¹

There was precipitating factor in 15 (38.5%) of our patients. Trauma either directly or indirectly was the most common etiological factor. Among the VAD, 7(38.9%) had a history of trauma, which is similar to as seen by Saeed *et al.*¹² According to the DONALD Investigators, 30% had a history of cervical trauma among the CAD which is similar to 8 (38.1%) as seen in our cohort.¹³

Among the VAD, neck pain was seen in 77.8%

individual's which is significantly higher than as seen by Gui *et al.* (10, 63%) and Marcel *et al.* (21, 10%).^{10,14} Among the VAD, neck pain (77.8%), vomiting (77.8%) and giddiness (72.2%) were the common presenting symptoms. Dysarthria (85.7%), vomiting (61.9%) and dysphagia 12 (57.1%) were the most common presenting features among the CAD which is similar to as seen by Lukas *et al* and Milhaud *et al.*^{11,15}

In our study, to diagnose dissection, multiple imaging modalities were required. 13 (72.2%) of VAD and 12 (57.1%) CAD underwent MRI + MRA + CTA. Doppler imaging was done in 13 (72.2%) and 18 (85.7%) of the VAD and of CAD respectively. As seen in other series, multimodal imaging is required for the diagnosis of carotid and vertebral artery dissection.^{10,11,16}

Majority of the VAD (94.4%) and CAD (80.9%) had extracranial segment involvement while extension into the intracranial segment was seen in few. This pattern of vessel involvement is seen in other series also.^{10,11}

The commonest treatment modality was

Table 6: Complications

	Vertebral Artery Dissection N=18	Carotid Artery Dissection N=21
Intrahospital (Acute)		
Pressure ulcer	0	4 (19.1%)
Deep vein thrombosis	0	2 (9.5%)
Dyselectrolytemia	1 (5.5%)	1 (4.8%)
Hemorrhagic transformation	1 (5.5%)	1 (4.8%)
Exposure keratitis	1 (5.5%)	0
Follow up (Chronic)		
Recurrent stroke	1 (5.5%)	0
Post stroke seizure	0	3 (14.3%)
Shoulder hand	0	1 (4.8%)
Neurogenic bladder	1 (5.5%)	0

Table 7: Modified Rankin Scale (mRS) score**7(a) Modified Rankin Scale (mRS) score - Vertebral artery dissection**

VAD Patient No.	Modified Rankin score (mRS)		
	At Discharge	3/12	6/12
1	5	LFU*	LFU
2	1	1	1
3	1	1	1
4	4	3	LFU
5	2	2	2
6	5	4	LFU
7	1	1	1
8	6	-	-
9	3	3	2
10	4	4	3
11	5	LFU	LFU
12	4	4	4
13	3	5	2
14	5	5	LFU
15	3	3	3
16	3	3	3
17	1	1	1
18	3	3	3

7(b) Modified Rankin Scale (mRS) score - Carotid artery dissection

CAD Patient No.	Modified Rankin Scale (mRS) score		
	At Discharge	3/12	6/12
1	4	4	4
2	1	1	1
3	4	4	3
4	3	3	2
5	1	1	1
6	4	LFU	LFU
7	4	3	3
8	4	3	3
9	3	3	3
10	4	LFU	LFU
11	4	3	3
12	4	4	6
13	3	3	3
14	3	3	3
15	4	LFU	LFU
16	4	3	3
17	4	4	LFU
18	3	3	3
19	3	2	1
20	3	2	1
21	3	3	3

* LFU: Lost to follow up

Table 8: Radiology - Follow up

	Vertebral Artery Dissection N = 18	Carotid Artery Dissection N=21
Lost to follow up (LFU)	5/17 (29.4%)	4/21 (19.1%)
Not assessed	4/12 (33.3%)	9/17(52.9%)
Doppler	3 (20%)	4 (23.5%)
MRI*	0	1 (5.9%)
CTA†	3 (20%)	2 (11.8 %)
CT‡	1 (8.3%)	1 (5.9%)

* MRI: Magnetic Resonance Imaging.

† CTA: Computerized Tomography Angiography.

‡ CT: Computed Tomography

antiplatelet plus anticoagulation i.e. 14 (77.8%) and 15 (71.4%) among VAD and CAD respectively which is higher as compared to patients in other large series. 97 (57.4%) among the VAD and 37(50.74%) among the CAD.^{10,11} There was 1 (5.5%) mortality among the VAD which was similar to 2 deaths (2% mortality) as seen by Arnold *et al.*¹⁰ While among the CAD the mortality was 1 (4.8%) as compared to 14% as seen by Milhaud *et al.*¹¹

Modified Rankin score (mRS) was used to assess the functional outcome after the stroke. MRs was ≤ 2 at discharge among 5/18 (28.8%) of the VAD and 7/21(9.5%) of the CAD. At 6 months, among the individuals followed up mRS was ≤ 2 in 7/12 (57.3%) and 5/17 (29.4%) of the VAD and CAD respectively.

In the VAD cohort, majority of individuals (93%) had mRS score ≤ 2 as seen by Arnold *et al.* which is similar to as seen in our study.¹⁰ MRs assessed at 3 months, majority of the VAD (10/15, 66.7%) had mRS ≤ 3 which was similar to as seen by Arnold *et al.* (93%). Milhaud *et al.* had assessed MRs at 1 month among the CAD which was < 3 in 46/73 (63.1%) while our CAD cohort it was 4/18 (22.2%) at 3 months.¹¹ DO (n = 73 In our study, mRS ≤ 2 was seen in 57.3% of the VAD and 29.4% of the CAD. Hence, our VAD cohort had a better functional outcome as compared to the CAD at 6 months.

In conclusion, a high index of suspicion for arterial dissection is needed in ischemic strokes among the young. A history of neck pain or trauma should not be missed. If arterial dissection is suspected as an etiology of stroke than multimodal imaging techniques may be required for confirming the diagnosis. The outcome appears to be good with 7/12 (57.3%) and 5/17 (29.4%) of the VAD and CAD respectively achieved an

mRS of ≤ 2 at 6 months follow up.

The limitations of this study were: This was a retrospective study and hence not all the data were available; our cohort was small; repeat imaging was not done in all the patients.

DISCLOSURE

Financial support: None

Conflict of interest: None

REFERENCES

1. Thanvi B, Munshi SK, Dawson SL, Robinson TG. Carotid and vertebral artery dissection syndromes. *Postgrad Med J* 2005;81(956):383-8.
2. Ohkuma H, Suzuki S, Ogane K, Study Group of the Association of Cerebrovascular Disease in Tohoku, Japan. Dissecting aneurysms of intracranial carotid circulation. *Stroke* 2002;33(4):941-7.
3. Schievink WI, Mokri B, Whisnant JP. Internal carotid artery dissection in a community. Rochester, Minnesota, 1987-1992. *Stroke* 1993;24(11):1678-80.
4. Giroud M, Fayolle H, André N, *et al.* Incidence of internal carotid artery dissection in the community of Dijon. *J Neurol Neurosurg Psychiatry* 1994; 57(11):1443.
5. Schievink WI, Bahram Mokri B, O'Fallon WM. Recurrent spontaneous cervical-artery dissection. *N Engl J Med* 1994;330:393-7.
6. Bassetti C, Carruzzo A, Sturzenegger M, Tuncdogan M. Recurrence of cervical artery dissection. *Stroke* 1996;27(10):1804-7.
7. Schievink WI. Spontaneous dissection of the carotid and vertebral arteries. *N Engl J Med* 2001;344(12):898-906.
8. Bogousslavsky J, Pierre P. Ischemic stroke in patients under age 45. *Neurol Clin* 1992;10(1):113-24.
9. Moonis G, Hwang CJ, Ahmed T, Weigle JB, Hurst RW. Otologic manifestations of petrous carotid aneurysms. *AJNR Am J Neuroradiol* 2005;26(6):1324-7.
10. Marcel A, Germaine BM, Gregor F, *et al.* *et al.*

- Vertebral artery dissection. *Stroke* 2006;37(10):2499-503.
11. Milhaud D, Freitas GR de, Melle G van, Bogousslavsky J. Occlusion due to carotid artery dissection: A more severe disease than previously suggested. *Arch Neurol* 2002;59(4):557-61.
 12. Saeed AB, Shuaib A, Al-Sulaiti G, Emery D. Vertebral artery dissection: warning symptoms, clinical features and prognosis in 26 patients. *Can J Neurol Sci* 2000;27(4):292-6.
 13. Christian L, Thierry M, Dominique D, Laurent T, Didier C. Stroke patterns of internal carotid artery dissection in 40 patients. *Stroke* 1998;29(12):2646-8.
 14. Gui L, Shi GS, Li GJ, *et al.* Spontaneous vertebral artery dissection: Report of 16 cases. *Neurol India* 2010;58(6):869.
 15. Mayer L, Boehme C, Toell T, *et al.* Local signs and symptoms in spontaneous cervical artery dissection: A single centre cohort study. *J Stroke* 2019;21(1):112-5.
 16. Shin JH, Suh DC, Choi CG, Lee HK. Vertebral artery dissection: Spectrum of imaging findings with emphasis on angiography and correlation with clinical presentation *RadioGraphics* 2000;20(6):1687-96.