

## Numbness and prolonged anosmia in a COVID-19 patient and the possibility of small fiber neuropathy: A case report

Small nerve fibers consist of small myelinated (A $\delta$ ) fibers and unmyelinated C fibers. These fibers are responsible for the small somatic and autonomic signal transmissions. Fibers of the olfactory nerves are also unmyelinated fiber hence considered small nerve fibers, although they were sheathed with olfactory ensheathing glia.<sup>1-4</sup>

There are some reported polyneuropathy cases related to coronavirus disease 2019 (COVID-19). Theoretically, the peripheral nerve damage here could be a result of the direct attack of the virus or through an immune-mediated mechanism.<sup>5,6</sup> Extrapulmonary clinical presentations of 2019 novel coronavirus disease (COVID-19) Small fiber neuropathy (SFN) is a type of neuropathy that is caused by damage to the small nerve fibers mentioned above.<sup>3,7</sup> To the best of our knowledge, no study has been addressed on discussing the role of SFN disorder in the clinical findings of COVID-19 patients.

A 42 years old female visited our clinic with a loss of smell and taste for a week. The symptoms started suddenly in the morning when she could not smell her coffee. One day after, she started to feel a numb and wet sensation on her hands and feet. Her husband was diagnosed as COVID-19 a week before. She was tested for severe acute respiratory syndrome coronavirus 2 (SARS-CoV-2) real-time polymerase chain reaction (RT-PCR) and the result was positive. Her hemoglobin was slightly reduced to 11.3g/dl and platelet increased to 630.000/ $\mu$ l. Leucocyte was normal (6.700/ $\mu$ l) with a neutrophil-to-lymphocyte ratio of 1.5.

She re-visited our clinic six weeks after the onset of her illness. At that time, she still complained about the reduced smell and also the numb and wet sensation of her hands and feet. On physical examination, her blood pressure was 140/90mmHg, heart-rate 76 bpm, axillary temperature 36.5°C, and oxygen saturation 97%. The general ENT examination showed normal appearance of nasal cavities. No hyperemic change and congestion to the nose. No polyps, septum deviation, or other obstruction in the nasal walls were noted. The throat and larynx were clear. Otoscopy shows no abnormality. On neurological examination, she can differentiate three types of smell given (coffee, tea, and tobacco) for each nostril but complained that the sensation was reduced. On the gustatory examination conducted using three different flavors (quinine, sugar, and salt solutions), the patient could identify all flavors correctly. Other cranial nerve tests were normal. Muscle tone and strength and physiological reflexes were normal and symmetrical. On exteroceptive sensory testing, she has no reduced sensation on pain, light touch, cold and warm water test. She also has a normal proprioceptive sensation as tested by two points discrimination, position, vibration and pressure tests. On nerve conduction study (NCS). Performed on bilateral median, ulnar, and radial nerves and also unilateral peroneal, tibial, and sural nerves, we found normal results for distal latencies, CMAPs/SNAPs, and nerve conduction velocities. However, her stimulated skin wrinkling using a eutectic mixture of lidocaine analgetic (SSW-EMLA) test performed on both hands showed a pathological result (Figure 1).

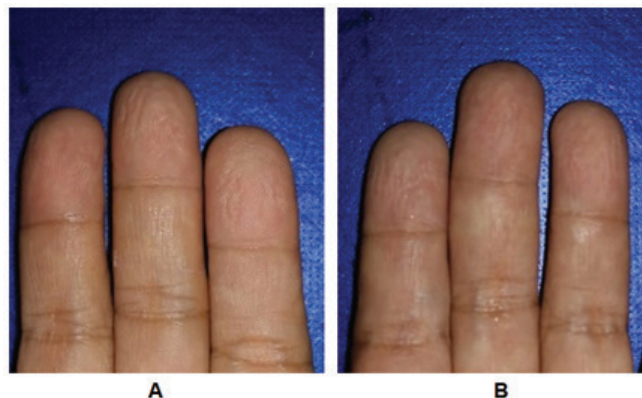


Figure 1. A. Right hand after SSW-EMLA test (score 1+3+2=6); B. Left hand after SSW-EMLA test (score 3+1+2=6). The final score was 6.

The presence of peripheral nerve disorder in COVID-19 patients has been reported by Mao *et al.* from their cohort in Wuhan, China.<sup>8</sup> The SSW is a reversible undulation phenomenon of the skin, mediated by an intact post-ganglionic sympathetic fiber that causes vasoconstriction in the glabrous skin. SSW-EMLA test has been shown to correlate with intraepidermal nerve fiber density in patients with sensory neuropathy. This test has been reported to yield good results in detecting SFN among diabetic, HIV, and leprosy patients.<sup>7,9,10</sup> Nevertheless, this test is still not widely accepted as a tool for assessing neuropathy.

The positive subjective finding of polyneuropathy (numbness and wet sensation) plus positive SSW-EMLA result and normal NCS result in this patient could suggest a SFN.<sup>7</sup> The authors could not find any report on the specific immune-mediated process to small nerve fibers in SARS-CoV-2 infection. Furthermore, there is no report about the expression of the ACE-2 receptor in the small nerve fibers. Based on these facts we assume that general inflammation could better explain the symptom. General inflammation has been reported in COVID-19 cases as a result of the release of various inflammatory mediators including the cytokines and could present in a mild to severe fashion and contributes to the severity of the disease.<sup>11-13</sup> From our perspective, it is possible that in mild COVID-19 patients, the inflammation only damages the small nerve fiber.

No report has specifically studied the concurrence between polyneuropathy and olfactory disorders in COVID-19. However, we think that it is possible since the reported cohorts and serial case reports of COVID-19 patients showed that the subjects with peripheral nerve symptoms or olfactory disorders were likely to have more than one symptom.<sup>8,14,15</sup>

Polyneuropathy and prolonged anosmia may share a common pathomechanism, the mild general inflammation. Depart from this argument, we suggest that a polyneuropathy screening and a quantified evaluation of the olfactory function should be added in the evaluation panel for COVID-19 patients.

In conclusion, the SFN could be considered a mild or early form of the polyneuropathy of multiple etiology including general inflammation. Prolonged anosmia also could suggest extended damage to the small fibers of olfactory nerves. This disorder needs more attention in the evaluation of COVID-19 cases.

Arthur HP Mawuntu MD, Herlyani Khosama MD

<sup>1</sup>Neurology Department Faculty of Medicine Sam Ratulangi University & Prof R.D. Kandou Hospital, Manado, Indonesia

**Keywords:** COVID-19, numbness, anosmia, small fiber neuropathy.

**Address correspondence to:** Dr Arthur HP Mawuntu MD, 1Neurology Department Faculty of Medicine Sam Ratulangi University & Prof R.D. Kandou Hospital, Manado, Indonesia. E-mail: arthur\_mawuntu@yahoo.com

## DISCLOSURE

Financial support: None

Conflict of interest: None

## REFERENCES

1. Wilder-Smith EP V. Stimulated skin wrinkling as an indicator of limb sympathetic function. *Clin Neurophysiol* 2015;126(1):10-6.
2. Myers MI, Peltier AC. Uses of skin biopsy for sensory and autonomic nerve assessment. *Curr Neurol Neurosci Rep* 2013;13(1):323.
3. Hovaguimian A, Gibbons CH. Diagnosis and treatment of pain in small fiber neuropathy. *Curr Pain Headache Rep* 2011;15(3):193-200.
4. Garcia-Gonzalez D, Murcia-Belmonte V, Clemente D, Castro F De. Olfactory system and demyelination. *Anat Rec* 2013;296(9):1424-34.
5. Ghiasvand F, Ghadimi M, Ghadimi F, Safarpour S, Hosseinzadeh R, SeyedAlinaghi SA. Symmetrical polyneuropathy in coronavirus disease 2019 (COVID-19). *ID Cases* 2020;21:e00815.
6. Beghi E, Feigin V, Caso V, Santalucia P, Logroscino G. COVID-19 Infection and neurological complications: Present findings and future predictions. *Neuroepidemiology* 2020; 54(5): 364-9.

7. Ng KWP, Ong JY, Nyein TDN, *et al.* EMLA-induced skin wrinkling for the detection of diabetic neuropathy. *Front Neurol* 2013;4:1-7.
8. Mao L, Jin H, Wang M, *et al.* Neurologic manifestations of hospitalized patients with coronavirus disease 2019 in Wuhan, China. *JAMA Neurol* 2020;77(6):683-90.
9. Mawuntu AHP, Mahama CN, Khosama H, Estiasari R, Imran D. Early detection of peripheral neuropathy using stimulated skin wrinkling test in human immunodeficiency virus infected patients: A cross-sectional study. *Medicine* 2018;97(30): e11526.
10. Verawati V. Sensitivity and specificity of Stimulated Skin Wrinkle examination against Sudoscan to detect autonomic neuropathy in multibacillary leprosy. Published online 2015. [http://lib.ui.ac.id/file?file=digital/2016-5/20417150-SP-Vivi Verawati.pdf](http://lib.ui.ac.id/file?file=digital/2016-5/20417150-SP-Vivi%20Verawati.pdf).
11. Baig AM, Sanders EC. Potential neuroinvasive pathways of SARS-CoV-2: Deciphering the spectrum of neurological deficit seen in coronavirus disease-2019 (COVID-19). *J Med Virol.* 2020;92(10):1845-57.
12. Thevarajan I, Nguyen THO, Koutsakos M, *et al.* Breadth of concomitant immune responses prior to patient recovery: a case report of non-severe COVID-19. *Nat Med.* 2020;26:450-5.
13. Susilo A, Rumende CM, Pitoyo CW, *et al.* Coronavirus disease 2019: Tinjauan literatur terkini. *J Penyakit Dalam Indones* 2020;7(1):45.
14. Liu J, Zhang S, Wu Z, *et al.* Clinical outcomes of COVID-19 in Wuhan, China: a large cohort study. *Ann Intensive Care* 2020;10(1):article no. 99.
15. Gutiérrez-Ortiz C, Méndez-Guerrero A, Rodrigo-Rey S, *et al.* Miller Fisher syndrome and polyneuritis cranialis in COVID-19. *Neurology* 2020;95(5):e601-e605.