

# Exercise-induced acute renal failure with posterior reversible encephalopathy syndrome

<sup>1</sup>Aysun Toraman, <sup>2</sup>Aysin Kısabay, <sup>1</sup>Berna Gursel Eren, <sup>2</sup>Melike Batum, <sup>1</sup>Seyhun Kursat

<sup>1</sup>Division of Nephrology, Department of Internal Medicine, <sup>2</sup>Department of Neurology, Celal Bayar University, Manisa, Turkey

## Abstract

Posterior reversible encephalopathy syndrome (PRES) is characterized by headache, mental changes, epileptic seizures, visual disturbances, and transient changes in the posterior circulation system of the brain. Rhabdomyolysis is a clinical condition characterized by muscle pain, weakness, dark-colored urine, and elevated creatine kinase levels. The common causes of rhabdomyolysis are trauma, excessive fatigue and intense exercise. A 23-year-old male soldier developed rhabdomyolysis-induced acute kidney injury after intense exercise and secondary PRES. The patient also had generalized convulsive seizures. There is no similar case of PRES from acute renal failure induced by muscle injury previously reported in the literature.

**Keywords:** Posterior reversible encephalopathy syndrome, epileptic seizure, rhabdomyolysis, acute renal failure, hypertension

## INTRODUCTION

Posterior reversible encephalopathy syndrome (PRES) was first described in 1996 by Hinchey *et al.*<sup>1</sup> Known etiologies includes hemolysis, elevated liver enzymes, and low platelet count (HELLP) syndrome, immunosuppressive and cytotoxic drugs, hypertension accompanying renal failure, liver failure, collagen vascular diseases, thrombotic thrombocytopenic purpura, massive blood transfusion, HIV infection, acute intermittent porphyria and organ transplantation, hypertensive encephalopathy, preeclampsia, and eclampsia.<sup>1-2</sup>

Rhabdomyolysis is a clinical condition characterized by the breakdown of damaged skeletal muscle. The muscle breakdown causes the release of myoglobin into the bloodstream.<sup>3</sup> Classical presentation of rhabdomyolysis is muscle pain, weakness, dark-colored urine, and elevated creatine kinase levels greater than 5-10 times the normal range. Acute renal failure is the most common systemic complication and is a poor prognostic indicator.<sup>4</sup> Mechanisms of rhabdomyolysis-induced acute renal failure are hypovolemia, myoglobinuria and metabolic acidosis.<sup>5</sup>

We report here a young soldier had

rhabdomyolysis-induced acute kidney injury after intense exercise and secondary PRES.

## CASE REPORT

A 23-year-old male presented to emergency department with flank pain and dark urine. The patient performed fast and intensive exercise for 12 hours six days ago. After that he complained of flank pain and tea-colored urine that lasted for two days. He then had widespread muscle pain and decreased urine volume for the last two days. At the time of admission, vital signs were normal. On physical examination, auscultation revealed bilateral diminished breath sounds, and other system examinations were normal. He had no significant past medical history or drug use. There was no complaints of similar episodes during childhood.

After investigations, he was diagnosed as having rhabdomyolysis-induced acute renal failure (Table 1). Abdominal ultrasonography revealed bilateral increased kidney and renal parenchymal echogenicity (Grade 2). The mean Resistive Index (RI) were increased in renal doppler ultrasound. It was calculated as 0.86 at the right kidney and 0.87 at the left kidney, respectively. On the 2<sup>nd</sup> day of hospitalization, the patient complained of

Address correspondence to: Aysin Kısabay (Associated Prof), Division of Neurology, Department of Internal Medicine, University of Celal Bayar, Manisa, Turkey. Tel: 05362566809, email: aysinkisabay@hotmail.com

Date of Submission: 8 October 2019, Date of Acceptance: 9 June 2020

**Table 1: The laboratory values obtained in the patient's admission**

White blood cell (/mm <sup>3</sup> )	8700 (4500-10300)	Creatine kinase (IU/L)	3377 (32-294)
Hemoglobin (gr/dL)	11.8 (13.6-17.2)	Lactate dehydrogenase (IU/L)	641 (125-243)
Hematocrit (%)	36.3% (39.5-50.3)	Aspartate aminotransferase (IU/L)	95 (0-40)
Platelet (/mm <sup>3</sup> )	286 (142-424)	Alanine aminotransferase (IU/L)	312 (7-49)
MCV	81.7 (80-100)	Alkalene phosphatase (IU/L)	75 (45-129)
Reticulocyte%	2.2	Total bilirubin (mg/dL)	0.35 (0.2-1.2)
Glucose (mg/dL)	81 (80-105)	CK-MB (U/L)	62.75 (0-25)
BUN (mg/dL)	229 (6-20)	Troponin I $\mu$ U/mL	0.06 (0.02-0.06)
Creatinine (mg/dL)	9.05 (0.6-1.3)	Direct bilirubin (mg/dL)	0.3 (0.01-0.2)
Uric acid (mg/dL)	12.1 (2.6-6)	MDRD eGFR (ml/sc)	7.75
Sodium (mmol/L)	134 (136-145)	pH (arterial blood gas)	7.35 (7.35-7.45)
Potassium (mmol/L)	4.9 (3.5-5.1)	HCO <sub>3</sub> (arterial blood gas)	18 (23-29)
Calcium (mg/dL)	9.1 (8.4-10.2)	PCO <sub>2</sub> (arterial blood gas)	30.7 (35-45)
Chloride (mmol/L)	96 (98-107)	Density (urine)	1008 (1005-1030)
Phosphor (mg/dL)	6.2 (2.3-4.7)	Protein (urine)	200 (++)
Albumin (g/dL)	3.2 (3.2-4.8)	Hemoglobin (urine)	0.5 (++)
Total protein (g/dL)	5.9 (6.4-8.7)		

sudden blurred vision, severe headache described as bilateral, throbbing spreading from occipital lobe to frontal lobe with photophobia, nausea and vomiting. The patient was conscious, orientated and cooperative on examination. Other neurologic examination was normal. The optic disk margin appeared normal and visual acuity was within normal limits. Cranial computed tomography scan was normal, On flair and diffusion sequences of brain MRI, T2 signal increase was observed in the cerebellum, both cerebellar hemispheres, and the posterior cortex (occipital and posterior parietal lobes) of the brain, which was consistent with vasogenic edema (Figure 1). Cranial MR angiography revealed vasospasm in the vascular structure. No pathology was found in MR venography. All vasculitis and infectious causes were negative. Complement levels and thyroid function tests were at normal limits.

The blood pressure was 150/90 mm Hg. On the 4<sup>th</sup> day of hospitalization, blood pressure increased (180/120 mmHg) and it was thought that the patient had PRES from rhabdomyolysis induced acute renal failure with hypertensive encephalopathy, nitroglycerin infusion was started. On the 6<sup>th</sup> day of admission, there were two generalized tonic clonic seizures one in the morning and one in the evening at the same day. Electroencephalopathy showed generalized epileptiform discharges and generalized slowing

of the background rhythm. The patient was given intravenous and then oral sodium valproate. During the follow-up, he underwent hemodialysis 4 times and diuretic therapy. His urine output subsequently increased, and the renal functions returned to normal at the end of the third week. He had no seizures under the antiepileptic treatment. After 2 weeks, the patient's clinical, laboratory and rhabdomyolysis parameters improved and EEG was normal. One month after discharge, cranial MRI was normal. Antiepileptic drug was stopped.

## DISCUSSION

PRES is alternatively known as acute focal cerebral edema or potentially reversible encephalopathy, since the clinical condition is reversible, is not restricted to the posterior areas and white matter of the brain, but is also seen in other anatomical regions.<sup>2</sup>

The implicated pathogenesis involve endothelial dysfunction, it has been reported in chronic renal failure, lupus nephritis, and hemolytic uremic syndrome. The combination of vascular endothelial toxicity, capillary destruction, blood-brain barrier disorder and axonal swelling leads to vasogenic edema.<sup>6,7</sup>

The lesions and edema described in our case are seen especially in the diffusion and FLAIR MRI

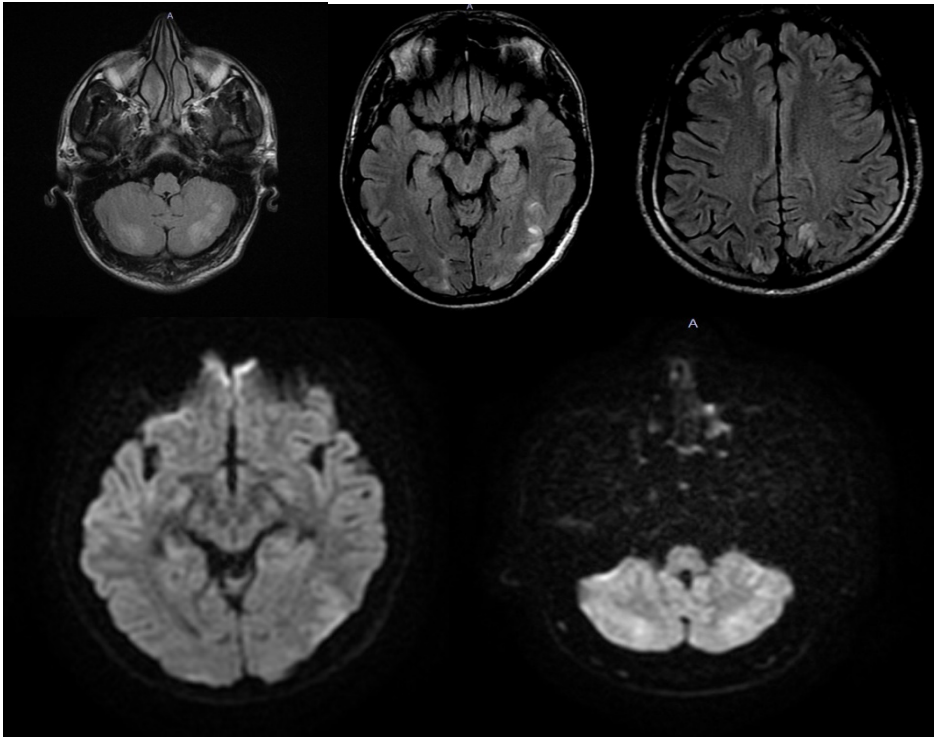


Figure-1: On FLAIR sequences of brain MRI, T2 signal increase was observed in the cerebellum, both cerebellar hemispheres, and the posterior cortex of the brain, and it was consistent with vasogenic edema. Bilateral occipital lobes and posterior parietal lobes showed a similar increase in cortical T2 signal. Diffusion MRI findings were consistent with vasogenic edema

sequences. In angiographic studies performed in patients with PRES due to hypertensive crisis, it was found that vasospasm developed in the posterior cerebral arteries.<sup>7</sup> In our case, MR angiography also revealed vasospasm and there was improvement of the symptoms after the treatment.

It is important to diagnose and treat PRES urgently to avoid irreversible damage. Our patient had resistant hypertension attacks which was gradually brought under control by intravenous antihypertensive drugs.<sup>8,9</sup>

Another common symptom seen in PRES

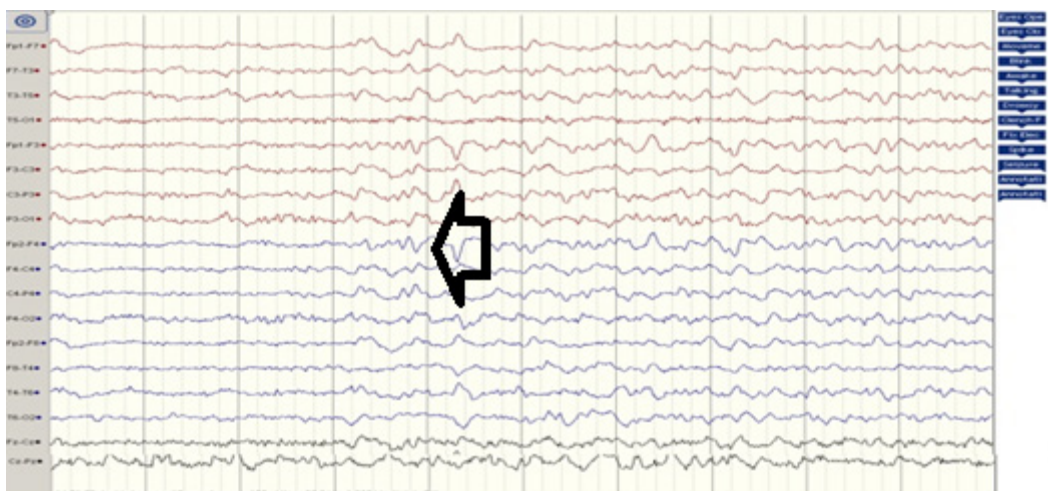


Figure 2: Generalized epileptiform abnormalities as well as widely decelerated ground rhythm

is convulsive seizures which may be focal or generalized.<sup>2,8</sup> Our patient had generalized convulsion twice. It is also important that the underlying disease should be identified and treated rapidly. In our case, acute renal failure from rhabdomyolysis resulting in PRES was quickly diagnosed and treated with hemodialysis and diuretic therapy, with the renal function returning to normal values.

Reviewing the medical literature, we found only one previous case that also had acute renal failure, PRES and rhabdomyolysis. However, the etiology of the case was from Influenza A.<sup>10</sup>

## REFERENCES

1. Hinchey J, Chaves C, Appignani B, *et al*. A reversible posterior leukoencephalopathy syndrome. *N Engl J Med* 1996; 334: 494-500.
2. Rodrigo P, Marik PE, Varon J. Posterior reversible encephalopathy syndrome. A Review. *Crit Care Shock* 2009;12(4):135-43.
3. Giannoglou GD, Chatzizisis YS, Misirli G. The syndrome of rhabdomyolysis: pathophysiology and diagnosis. *Eur J Intern Med* 2007;19(2):90-100.
4. Bosch X, Poch E, Grau JM. Rhabdomyolysis and acute kidney injury. *N Engl J Med* 2009;361(1): 62-72.
5. Boutaud O, Roberts LJ. Mechanism based therapeutic approaches to rhabdomyolysis induced renal failure. *Free Radic Biol Med* 2011;51(5):1062-7.
6. Bartynski WS. Posterior reversible encephalopathy syndrome, part 1: fundamental imaging and clinical features. *AJNR Am J Neuroradiol* 2008;29(6):1036-42.
7. Pande AR, Ando K, Ishikura R *et al*. Clinicoradiological factors influencing the reversibility of posterior reversible encephalopathy syndrome: A multicenter study. *Radiat Med* 2006; 24: 659-668.
8. Feske SK. Posterior reversible encephalopathy syndrome: a review. *Semin Neurol* 2011;31:202-15.
9. Vaughan CJ, Delanty N. Hypertensive emergencies. *Lancet* 2000;356:411-7.
10. Fearnley RA1, Lines SW, Lewington AJ, *et al*. Influenza A-induced rhabdomyolysis and acute kidney injury complicated by posterior reversible encephalopathy syndrome. *Anaesthesia* 2011;66(8):738-42.