

# Toxoplasmosis presenting with multiple cranial nerve palsies and cavernous sinusitis: A case report

\*Jing Liu, \*Beilin Zhang, \*Lexiang Cui, Teng Zhao, Ren sheng Zhang, Hongchao Liu, Heqian Du, Jiguo Gao, Shaokuan Fang

\*J Liu, BL Zhang & LX Cui contributed equally to the work

Department of Neurology, Neuroscience Center, the First Teaching Hospital of Jilin University, Changchun, China

## Abstract

Toxoplasmosis is a worldwide zoonosis caused by an intracellular protozoan parasite, *Toxoplasma gondii*. We report here a diabetic patient who was diagnosed as toxoplasmosis with multiple cranial nerve palsies and cavernous sinusitis. A 37-year-old male presented with an 11-day history of gingival pain, one day history of ptosis and diplopia. He has been having diabetes mellitus for 6 years, and has a history of contact with cats. After admission, his symptoms worsened with right 3<sup>rd</sup> to 7<sup>th</sup> cranial nerve palsies. The brain magnetic resonance imaging (MRI) showed cavernous sinusitis in the right sellar region. Serology for toxoplasma was positive for IgM and negative IgG. The patient was treated with oral clindamycin (900 mg/day) and dexamethasone (15 mg/day). The right visual acuity and lid-conjunctival swelling improved after 3 days. At follow-up after a month, the movement of the right eye significantly improved. This case demonstrate the rare occurrence of multiple cranial nerve (3<sup>rd</sup> to 7<sup>th</sup>) palsies from toxoplasmosis cavernous sinusitis, which is a potentially treatable condition.

**Keywords:** Toxoplasmosis; multiple cranial nerve palsies; cavernous sinusitis; case report

## INTRODUCTION

Toxoplasmosis is a zoonosis occurring worldwide caused by *Toxoplasma gondii*, an intracellular protozoan parasite which could cause a congenital or acquired infection. Toxoplasma encephalitis commonly manifests clinically as headache, fever, hemiparesis, ataxia, cranial nerve palsy and seizures.<sup>1</sup> Cats are the definitive hosts for *Toxoplasma gondii*, and the main transmission routes are ingestion of contaminated food or water; ingestion of raw or undercooked meat infected with the parasite; infected transplants; and maternal–infant vertical transmission.<sup>2</sup> In immunocompetent hosts, toxoplasmosis may manifest as fever, lymphadenopathy, maculopapular rash, myalgia or arthralgia. In immunodeficient individuals, clinical syndromes include encephalitis, myocarditis, pneumonitis, hepatitis, disseminated infection, and may be fatal.<sup>3</sup> Toxoplasmosis manifesting as multiple cranial nerve palsies is extremely rare and may be seen in human immunodeficiency virus (HIV) infection. Cavernous sinusitis from toxoplasmosis has not been reported previously.

We report here a diabetic patient who presented with multiple cranial nerve palsies from toxoplasmosis cavernous sinusitis.

## CASE REPORT

A 37-year-old male presented with 11-day history of gingival pain, one day history of ptosis and diplopia. The patient initially sought Chinese traditional medicine treatment of moxibustion without improvement. He has been having diabetes mellitus for 6 years, and a history of contact with cats. On admission, physical examination showed right ptosis, right eye movement limited to abduction, decreased tactile sensation in the right V1=2 dermatomes, and deviation of the jaw to the right side when he opened his mouth. There was also eyelid and conjunctival swelling. A day after admission, the symptoms worsened and examination showed dilated right pupil with impaired reaction to light; right eye had complete ptosis with no movement, and the right eye vision was blurred. He also has right right facial palsy. A diagnosis of 3<sup>rd</sup>~7<sup>th</sup> cranial nerve palsies was made (Figure 1). The

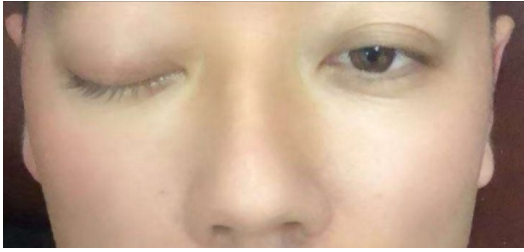


Figure 1. The patient presented with 3rd~7th cranial nerve palsies.

other neurological examinations were normal. Head computed tomography (CT) showed nasal sinusitis. MRI brain showed cavernous sinusitis in the right sellar region with a lesion that was homogeneously hypointense on T1-weighted imaging, homogeneously hyperintense on T2-weighted imaging, and a stripe-like enhancement on T1-weighted imaging with contrast, the maximal diameter was approximately 0.9 cm (Figure 2). MR angiography demonstrated some irregularities from atherosclerosis. The visual acuity of the right eye was 0.15, and that of the left eye was 0.9. Intraocular pressure was normal in both sides, and fundal photography was normal. Blood examination revealed leukocytosis ( $12.22 \times 10^9/L$ ) with 81.8% neutrophil, raised random blood glucose level (25 mmol/L), fasting blood glucose level (14 mmol/L), glycosylated hemoglobin level (16.1%), and strongly positive urine glucose. The following parameters were all normal or negative: HIV-related antibody, tumor markers, anti-nuclear antibodies, anti-cardiolipin antibodies, and tuberculosis-related antibody. Lumbar puncture showed normal opening pressure of 180 cmH<sub>2</sub>O. Cerebrospinal fluid (CSF) examination showed leukocytosis (190 with 83% lymphocyte), raised glucose (9.6 mmol/L) and protein levels (460 mg/L). Serology for toxoplasma was positive for IgM and negative

for IgG in the blood, but both IgM and IgG were negative in CSF. Cryptococcal smear and tuberculosis-related antibody were both negative in CSF. As the patient was allergic to sulfadiazine, he was treated with oral clindamycin (900 mg/day) and dexamethasone (15 mg/day). He was also given insulin infusion to control the blood glucose. Three days after initiation of the anti-toxoplasma and dexamethasone treatment, the right visual acuity and lid-conjunctival swelling improved significantly. At follow-up in one month, the movement of the right eye also significantly improved.

## DISCUSSION

We believe this patient's cavernous sinusitis with multiple cranial palsy was from toxoplasmosis infection. This was based on the positive IgM serology. The negative IgG serology may be from the immunosuppressed status. The response to anti-toxoplasma and dexamethasone treatment was also supportive of toxoplasmosis.

Toxoplasmosis is a common opportunistic infection in acquired immune deficiency syndrome (AIDS) patients, which can present with variable manifestations depending on the organs involved. Clinical manifestations of toxoplasma encephalitis include headache, fever, hemiparesis, ataxia, cranial nerve palsy, seizures, chorea, rigidity, and ballism.<sup>1</sup> In ocular toxoplasmosis, retinal scars, vitritis, retinal detachment and optic neuritis may occur.<sup>4</sup>

The mechanism by which *Toxoplasma gondii* enter the central nerve system remains controversial. Oscar *et al.* proposed that the parasite passes through the blood-brain barrier, which is similar to the intestinal epithelium, via the actomyosin movements. Another hypothesis was that tachyzoites in blood invade the vascular endothelium and replicate in the central nervous

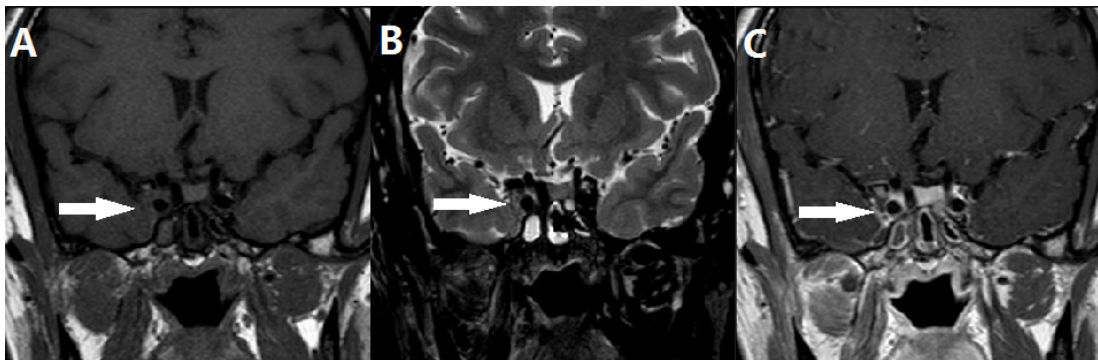


Figure 2. Brain MRI of the patient. Brain MRI showed cavernous sinusitis (white arrow) in the right sellar region.

system. The immune cells infected by parasites may promote the mobility of *Toxoplasma gondii* across the endothelial barrier.<sup>5</sup> On neuroimaging, toxoplasma encephalitis exhibits rounded lesions located in gray-white junction, deep white matter and basal ganglia, exhibiting isodensity or hyperdensity with ring or homogeneous contrast enhancement.<sup>1</sup>

Cranial nerve palsies in patients with toxoplasmosis are uncommon. Pillay *et al.* reported 22 cases of cranial nerve deficiency in HIV-infected patients, and only one patient was definitively diagnosed with toxoplasmosis.<sup>6</sup> Mowatt *et al.* described 3rd and 6th cranial nerve defects secondary to toxoplasma and cryptococcosis meningitis in HIV-infected patients.<sup>7</sup> Mwanza *et al.* reported 11 HIV-infected patients with toxoplasmosis, among whom 4 cases had 3rd cranial nerve palsy and 7 had 6th cranial nerve palsy.<sup>8</sup> The predisposition to 3<sup>rd</sup> and 6<sup>th</sup> cranial nerve involvement may reflect a mass effect from the toxoplasmosis as common cause of the nerve palsy.

Riga *et al.*, Couvreur *et al.* and Galli-Tsinopoulou *et al.* each reported a case of toxoplasmosis accompanied by facial nerve palsy.<sup>3,9,10</sup> Optic neuritis caused by acquired toxoplasmosis has also been reported.<sup>11</sup> Riga *et al.* demonstrated the mechanism of toxoplasma-induced facial nerve palsy; where the parasites may move alone or be transferred via white cells from the intestinal lumen to the vascular endothelial cells, affecting the motor neurons of the facial nerve, and activating the immune response. Another possibility may be the epitope homologies between the parasite and host peripheral nervous system molecules.<sup>9</sup>

Our patient was negative for HIV antibodies, but his diabetes may result in impairment of immune function, resulting in the susceptibility to toxoplasma infection. On MRI, no white matter lesion was noted, and we observed a lesion in the right cavernous sinus, a rare site for toxoplasmosis. The 3<sup>rd</sup> to 6<sup>th</sup> nerve palsy may be explained by the cavernous sinusitis, with involvement of the nerves at the vicinity of the cavernous sinus. The spread of infection from the cavernous sinus to the adjacent petrous bone may result in the facial palsy. The pleocytosis in the CSF examination indicated the presence of meningeal inflammation, with possible involvement of the facial nerve as another possibility. As discussed above, the facial nerve involvement may also be a migration of the parasite from the intestinal epithelial cells to vascular endothelial cells, genicular ganglion

or facial motor neuron, resulting in ischemia or immune damage. But the facial palsy being from the same side make this less likely.

## ACKNOWLEDGEMENTS

We would like to thank the patient and his family.

## DISCLOSURE

Financial support: This work was supported by the National Natural Science Foundation of China (81873794).

Conflict of interest: None

## REFERENCES

1. Marra CM. Central nervous system infection with *Toxoplasma gondii*. *Handb Clin Neurol* 2018;152: 117-22.
2. Fakhar M, Soosaraei M, Khasseh AA, Emameh RZ, Hezarjaribi HZ. A bibliometric analysis of global research on toxoplasmosis in the Web of Science. *Vet World* 2018;11(10):1409-15.
3. Galli-Tsinopoulou A, Kyrgios I, Giannopoulou EZ, *et al.* Acquired toxoplasmosis accompanied by facial nerve palsy in an immunocompetent 5-year-old child. *J Child Neurol* 2010;25(12): 1525-8.
4. Delair E, Latkany P, Noble AG, Rabiah P, McLeod R, Brézin A. Clinical manifestations of ocular toxoplasmosis. *Ocul Immunol Inflamm* 2011;19(2): 91-102.
5. Mendez OA, Koshy AA. *Toxoplasma gondii*: Entry, association, and physiological influence on the central nervous system. *PLoS Pathog* 2017;13(7): e1006351.
6. Pillay S, Ramchandre K. Audit of computed tomography brain findings in HIV-infected patients with space occupying infective lesions at a regional level hospital in KwaZulu-Natal. *SAGE Open Med* 2018;6: 2050312118801242.
7. Mowatt L. Ophthalmic manifestations of HIV in the highly active anti-retroviral therapy era. *West Indian Med J* 2013;62(4): 305-12.
8. Mwanza JC, Nyamabo LK, Tylleskär T, Plant GT. Neuro-ophthalmological disorders in HIV infected subjects with neurological manifestations. *Br J Ophthalmol* 2004;88(11):1455-9.
9. Riga M, Kefalidis G, Chatzimoschou A, *et al.* Increased seroprevalence of *Toxoplasma gondii* in a population of patients with Bell's palsy: a sceptical interpretation of the results regarding the pathogenesis of facial nerve palsy. *Eur Arch Otorhinolaryngol* 2011;268(7):1087-92.
10. Couvreur J, Thulliez P. Acquired toxoplasmosis of ocular or neurologic site: 49 cases. *Presse Med* 1996;25(9):438-42.
11. Roach ES, Zimmerman CF, Troost BT, Weaver RG. Optic neuritis due to acquired toxoplasmosis. *Pediatr Neurol* 1985;1(2):114-6.