

## REVIEW ARTICLE

# The pathogenic mechanisms of motor weakness following aneurysmal subarachnoid hemorrhage: A review

Sung Ho Jang MD, Han Do Lee MS

Department of Physical Medicine and Rehabilitation, College of Medicine, Yeungnam University, Taegu, Korea

### Abstract

Motor weakness is one of the neurological complication that can occur after aneurysmal subarachnoid hemorrhage (SAH); incidence of motor weakness of 14~29% has been reported. Detailed information on the pathogenic mechanism of motor weakness is essential for brain rehabilitation because it enables estimation of the severity of injury, establishment of scientific rehabilitative strategies, and prediction of motor outcomes by clinicians. However, the exact pathogenic mechanisms of motor weakness following aneurysmal SAH have not been clearly elucidated. In this article, 14 previous studies on pathogenic mechanisms in patients with aneurysmal SAH were reviewed according to the location of the lesion (cerebral cortex, brainstem, spinal cord, and peripheral nerve). The following pathogenic mechanisms have been suggested: vasospasm, cerebral ischemia, hydrocephalus, compression of cerebral cortex, neural injury, spinal cord infarction, and radiculo-neuropathy. Considering the high incidence of aneurysmal SAH and motor weakness following aneurysmal SAH, we believe that the pathogenic mechanisms of motor weakness have been relatively understudied. More effort should be taken to investigate this important topic.

*Keywords:* Subarachnoid hemorrhage, aneurysm, motor weakness, hemiplegia, paraplegia, quadriparesis.

### INTRODUCTION

Aneurysmal subarachnoid hemorrhage (SAH) involves bleeding into the subarachnoid space between the arachnoid membrane and the pia mater covering the brain following rupture of an aneurysm. Motor weakness is one of the neurological complications that can occur after aneurysmal SAH, along with somatosensory deficit, cranial nerve dysfunction, visual dysfunction, and consciousness disturbance.<sup>1-3</sup> Incidence of motor weakness in aneurysmal SAH of 14~29% has been reported.<sup>1,3-6</sup> Detailed information on the pathogenic mechanism of motor weakness is essential for brain rehabilitation because it enables estimation of the severity of injury, establishment of scientific rehabilitative strategies, and prediction of motor outcomes by clinicians.<sup>7</sup> However, the exact pathogenic mechanisms of motor weakness following aneurysmal SAH have not been clearly elucidated. The following pathogenic mechanisms of motor

weakness in patients with aneurysmal SAH have been suggested: vasospasm, cerebral ischemia, hydrocephalus, compression of neural structure, neural injury, spinal cord infarction, and peripheral neuropathy.<sup>3,7-19</sup>

In this article, previous studies on the pathogenic mechanisms of motor weakness in patients with SAH following aneurysmal rupture were reviewed. Relevant studies were identified using two electronic databases (Pubmed and MEDLINE) from 1966 to 2014. The following key words were used: SAH, aneurysm, motor weakness, hemiplegia, paraplegia, paraparesis, and quadriparesis. This review was limited to studies that included convincing evidence on the pathogenic mechanisms of motor weakness in patients with SAH, therefore, studies that did not show definite evidence of motor weakness were excluded.<sup>20,21</sup> Finally, 14 studies were selected and classified according to the location of the lesion and pathogenic mechanisms, as follows:

*Address correspondence to:* Dr Han Do Lee, Department of Physical Medicine and Rehabilitation, College of Medicine, Yeungnam University, 317-1, Daemyungdong, Namku, Taegu, 705-717, Republic of Korea. Tel: 82-53-620-4098, e-mail: lhd890221@hanmail.net

1) cerebral cortex (8 papers); vasospasm and cerebral ischemia - 6 papers, hydrocephalus - one paper, and compression of the cerebral cortex- one paper, 2) brainstem (3 papers); neural injury - 3 papers, and 3) spinal cord and peripheral nerve (three papers); spinal cord infarction - 2 papers and peripheral neuropathy - one paper.<sup>3,7-19</sup> A flow diagram of the study selection process is shown in Figure 1.

**CEREBRAL CORTEX**

Eight papers on lesions in the cerebral cortex were classified as follows: three pathogenic mechanisms: vasospasm and cerebral ischemia (6 papers), hydrocephalus (one paper), and compression of the cerebral cortex (one paper).<sup>8,9,11-15,17</sup>

**Vasospasm and cerebral ischemia**

Vasospasm and cerebral ischemia are the most commonly reported pathogenic mechanisms of motor weakness in patients with aneurysmal SAH (6 of 14 papers).<sup>8,9,11-15,17</sup> In 1986, Maiuri *et al.* reported on a patient who showed

weakness of both legs as the first symptom of a ruptured anterior communicating artery (ACoA) aneurysm.<sup>9</sup> The patient became paraplegic within 12-36 hours after onset and the brain CT showed small lacunar ischemic hypodense lesions in both high frontoparietal parasagittal regions. The authors concluded that insufficient blood perfusion of both paracentral areas was the cause of paraplegia. In 1995, in a study by Greene *et al.* for clinicopathologic evaluation of patients with paraparesis following rupture of ACoA aneurysms<sup>11</sup>, 7 of 101 patients with SAH from ruptured ACoA aneurysms were recruited. Angiographic evidence of vasospasm in the anterior cerebral artery (ACA) distribution was documented in all cases, and paraparesis persisted beyond the angiographic resolution of vasospasm: motor weaknesses developed within 7 days of aneurysm rupture and persisted for a mean duration of 39 days. Pathologic analysis of autopsy material from one patient showed laminar necrosis in the parasagittal distribution of the ACA, indicating microvascular ischemia and infarction. All patients showed cognitive (memory impairment) and affective (affect

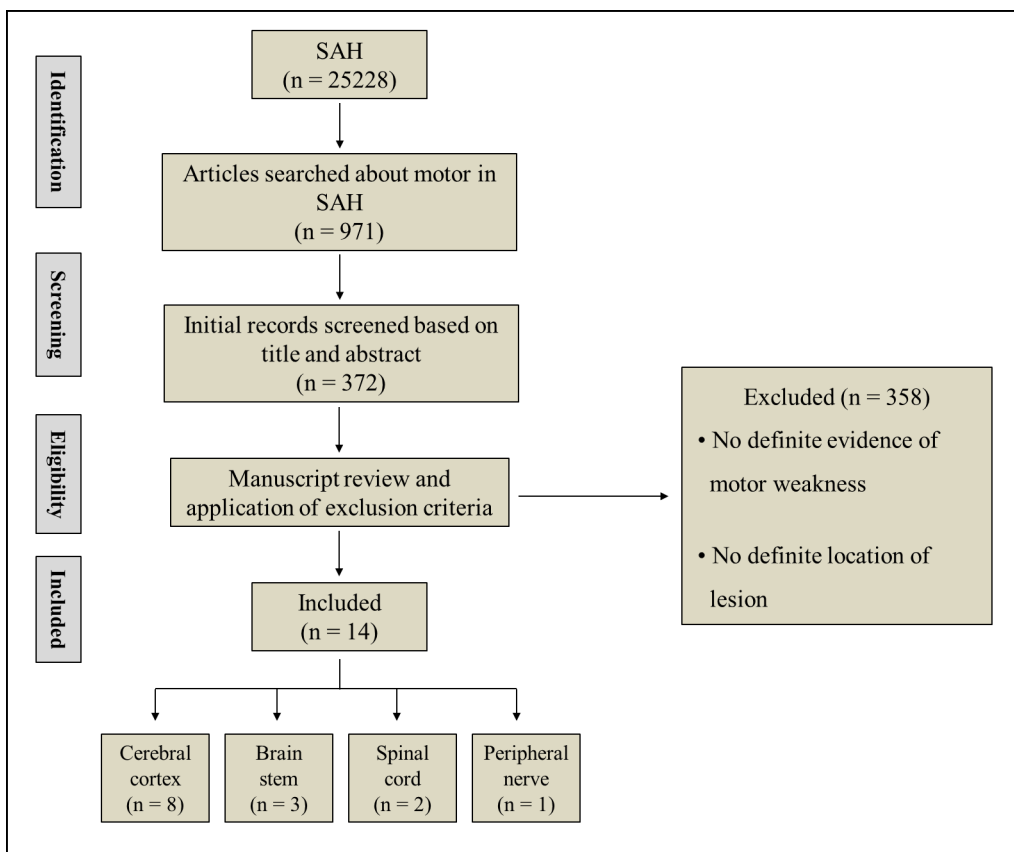


Figure 1: Flow diagram of study selection. SAH; subarachnoid hemorrhage.

flattening) manifestations. The authors proposed that this combination of lower limb weakness with cognitive and affective dysfunctions be referred to as the ACoA aneurysm paraparesis syndrome. Subsequently, Kombos *et al.* reported on a patient who developed paraplegia one week after rupture of an ACoA aneurysm.<sup>12</sup> Brain CT showed cerebral infarction in the bilateral frontomedial areas, which are supplied by the ACAs. In 2000, Warrenburg *et al.* reported on a patient who showed symmetrical proximal muscle weakness of the legs (Medical Research Council grade: 4).<sup>13</sup> Brain MRI at nine days after the initial headache showed residual blood in the anterior interhemispherical fissure. Brain MR angiography showed an aneurysm of the ACoA and extreme spasm of both ACAs. Consequently, they assumed that the proximal weakness of the legs was the result of ischemia of the medial parts of the frontal lobes secondary to spasm of both ACAs. In 2005, Endo *et al.* reported on 9 of 178 patients with ruptured aneurysms of ACoA or ACA who presented with paraparesis.<sup>14</sup> In 4 of the 9 patients, diffusion-weighted brain MRI performed within 48 hours of onset of SAH showed high-intensity lesions in the medial aspects of the bilateral frontal lobes, which were supplied by the ACAs. Normal to subnormal values of apparent diffusion coefficient (ADC) were observed for these high-intensity lesions. Most high-intensity lesions recovered and did not result in final lesions, regardless of the ADC values, but some lesions with subnormal ADC values resulted in cerebral infarction. Three patients showed complete recovery and the remaining one patient showed partial recovery. Teufack *et al.* recently reported on a patient who presented with SAH with intraventricular extension.<sup>17</sup> The patient was treated with coil embolization of an ACoA aneurysm. Postoperatively, the patient was found to have weakness of both ankle and toe dorsiflexion, and brain MRI showed acute infarction in the parasagittal bifrontal gyriiform areas.

### **Hydrocephalus**

In 2008, Johnston *et al.* reported on six of 695 patients who presented with profound paraparesis after SAH following rupture of an aneurysm (ACoA: one patient, posterior communicating artery (PCoA): one patient, posteroinferior cerebellar artery [PICA]: 2 patients, and ACoA and internal carotid artery: one patient).<sup>15</sup> These patients showed hydrocephalus and all patients

required urgent ventriculostomy for hydrocephalus (5 patients went on to require permanent shunt placement). Five of the 6 patients showed gradual resolution of their paraparesis over the course of 3 to 6 months: one patient - walker gait at 6 months, one patient - wide based gait at 3 years, 2 patients - normal gait at 3 weeks and 6 months, respectively, one patient - abnormal tandem gait at 16 months, and one patient - minimal improvement at 3 weeks. Based on these results, they suggested that hydrocephalus was the cause of paraparesis of these patients.

### **Compression of cerebral cortex**

In 1984, Kudo and Uno reported on a patient who presented with ipsilateral hemiparesis following a ruptured middle cerebral artery aneurysm.<sup>8</sup> The patient had a moderate right hemiparesis with the upper extremity weaker than the lower extremity. Brain CT showed SAH in the basal cistern, ambient cistern, and the cistern of the Sylvian fissure: the SAH was most severe in the right cistern of the Sylvian fissure. Therefore, they concluded that the ipsilateral hemiparesis was most likely due to compression of the secondary motor area in the island of Reil by SAH.

## **BRAINSTEM**

### **Neural injury**

To the best of our knowledge, three studies on neural injury at the brainstem level have been reported.<sup>3,7,19</sup> In 1992, Ferrante *et al.* reported on a patient who showed contralateral leg weakness following SAH from an aneurysm of the first PICA segment.<sup>3</sup> The patient showed complete recovery from the motor weakness at three months after onset. They assumed that the corticospinal tract of the contralateral leg was affected by SAH and/or spasm of branches of the PICA. In 2012, Yeo *et al.* investigated corticospinal tract injury in patients with spontaneous SAH using diffusion tensor imaging (DTI).<sup>7</sup> Twenty two patients who showed quadriplegia (19 patients) and hemiparesis (3 patients) with no lesion in the cerebral cortex were recruited and DTI parameters of the corticospinal tract were measured. They found partial injury of the whole corticospinal tract in patients with SAH and the injury level appeared to be at the midbrain. They suggested that injury of the corticospinal tract occurred at the midbrain due to its close proximity to the cistern by mechanical (increased intracranial pressure or direct mass effect by SAH) or chemical (blood clot

**Table 1: Previous studies on motor weakness in patients with aneurysmal subarachnoid hemorrhage**

Lesion location	Pathogenic mechanism	Authors	Publication year	Patients	Weakness	Evaluation tool	Results	
<b>Cerebral Cortex</b>	Vasospasm & Cerebral ischemia	Maiuri <i>et al.</i> <sup>8</sup>	1986	1	Paraplegia	Brain CT	Cerebral ischemia	
		Greene <i>et al.</i> <sup>9</sup>	1995	7	Paraparesis	Cerebral angiography	Vasospasm	
						Pathology	Microvascular ischemia	
			Kombos <i>et al.</i> <sup>10</sup>	1996	1	Paraplegia	Brain CT	Cerebral infarction
			Warrenburg <i>et al.</i> <sup>11</sup>	2000	1	Symmetrical proximal leg weakness	Brain MRA	Vasospasm
			Endo <i>et al.</i> <sup>12</sup>	2005	9	Paraparesis	Diffusion-weighted brain MRI (4 Patients)	High intensity lesion in bilateral medial frontal lobes
			Teufack <i>et al.</i> <sup>13</sup>	2011	1	Bilateral foot drop	Brain MRI	Acute infarction
		Hydrocephalus	Johnson <i>et al.</i> <sup>14</sup>	2008	6	Paraparesis	Brain CT	Hydrocephalus
		Compression of cerebral cortex	Kudo & Uno <sup>15</sup>	1984	1	Ipsilateral hemiparesis	Brain CT	Compression of secondary motor area by SAH
<b>Brainstem</b>	Neural injury	Ferrante <i>et al.</i> <sup>2</sup>	1992	1	Contralateral leg weakness	Brain CT	CST injury by SAH	
		Yeo <i>et al.</i> <sup>7</sup>	2012	22	Quadriparesis or hemiparesis	DTI	CST injury at midbrain	
		Jang <i>et al.</i> <sup>16</sup>	2014	12	Contralateral proximal weakness	DTI	CRP injury at midbrain	
<b>Spinal cord &amp; Peripheral nerve</b>	Spinal cord infarction	Kashiwagi <i>et al.</i> <sup>19</sup>	1992	1	Paraplegia	MRI	Unilateral lesion in upper spinal cord	
		Krishna <i>et al.</i> <sup>17</sup>	2012	1	Paraplegia	Spine MRI	Spinal cord infarction	
		Radiculoneuropathy	Kostov <sup>18</sup>	2010	2	Leg monoparesis	Lumbar MRI	Radiculoneuropathy

CT: computed tomography, MRA: magnetic resonance angiography, MRI: magnetic resonance imaging, SAH: subarachnoid hemorrhage, DTI: diffusion tensor imaging, CST: corticospinal tract, CRP: corticoreticular pathway.

itself can cause extensive damage or release of potentially damaging substances, such as free iron, which may generate free radicals or inflammatory cytokines) factors by SAH.<sup>22-25</sup> Jang *et al.* recently reported injury of the corticoreticular pathway (CRP) in 17 patients who showed contralateral proximal weakness with no lesion in the cerebral cortex among 137 patients with aneurysmal SAH (ACoA-14 patients, PCoA: one patient, ACA: one patient, and internal carotid artery: one patient. Twelve (70.6%) of 17 patients and 18 (52.9%) of 34 hemispheres showed a discontinuation of the CRP at the midbrain level. Therefore, they concluded that either mechanical or chemical injury of the corticoreticular pathway by SAH had occurred at the midbrain, although the location of the corticoreticular pathway is deeper than that of the corticospinal tract in the midbrain.<sup>22,26,27</sup>

## SPINAL CORD AND PERIPHERAL NERVE

### Spinal cord infarction

Two studies on spinal cord infarction following aneurysmal SAH have been reported.<sup>10,18</sup> In 1992, Kashiwagi *et al.* reported on a patient who showed paraplegia following a ruptured aneurysm of the distal PICA.<sup>10</sup> The patient regained walking ability at 3 months after onset and returned to walking at 6 months after onset. MRI showed a vascular lesion in the subarachnoid space adjacent to the spinal cord at the level of C1. Based on this finding, the authors concluded that the patient's paraplegia was caused by a unilateral lesion located between the cervicomedullary junction and the C2 level, involving both crossed and uncrossed CST fibers projecting to the lower extremities. Krishna *et al.* recently reported on a patient who showed sudden onset of SAH by the rupture of an aneurysm of

ACoA.<sup>18</sup> Nine days after aneurysmal rupture, the patient was found to be paraplegic. Spine MRI showed subarachnoid blood in the lumbo-sacral subarachnoid space along with signal abnormality within the spinal cord at the level of the conus extending from T11-L1 and multiplanar spin echo diffusion weighted imaging confirmed spinal cord stroke in this region.

### Radiculo-neuropathy

In 2010, Kostov *et al.* reported on two patients who presented with acute SAH from a ruptured intracranial aneurysm (PCoA and ophthalmic artery).<sup>16</sup> Both patients were treated by endovascular coil embolization, and both developed delayed unilateral lower extremity weakness without associated symptoms, which resolved over the ensuing months. Lumbar MRI showed significant layering of blood products in the dependent portion of the thecal sac from L3 down to the S2 level. Based on this finding, they concluded that the painless neuropathy likely resulted from nerve root irritation from abundant subarachnoid blood in the lumbar cistern.

## CONCLUSION

In this mini-review article, 14 previous studies on pathogenic mechanisms of motor weakness in patients with aneurysmal SAH were reviewed according to the location of the lesion (cerebral cortex, brainstem, spinal cord, and peripheral nerve). The pathogenic mechanisms of motor weakness were summarized as follows: vasospasm, cerebral ischemia, hydrocephalus, compression of the cerebral cortex, neural injury, spinal cord infarction, and peripheral neuropathy.<sup>3,7-19</sup> Figure 2 and Table 2 showed a pie chart and

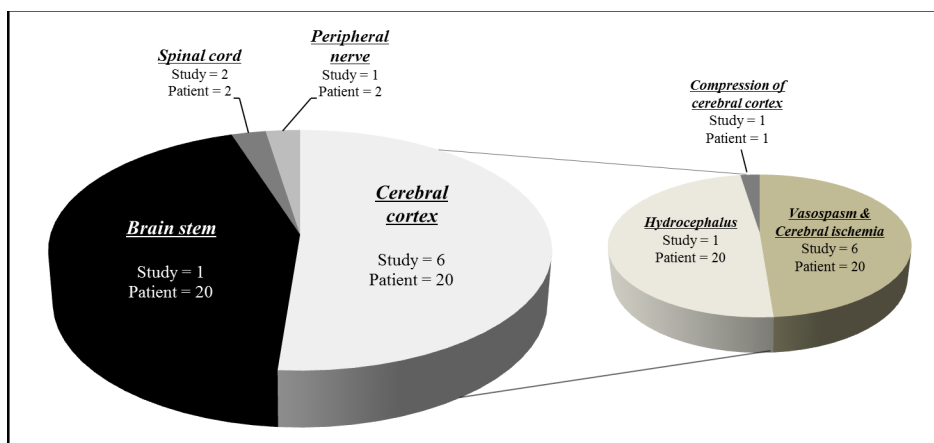


Figure 2: A pie chart about the number of studies and patients.

**Table 2: A cross-table about the number of studies and patients in each pathogenic mechanism**

Syndrome	Mechanism	Number of patients	Remarks
Paraparesis/paraplegia	Vasospasm and cerebral ischemia	18	
	Hydrocephalus	6	
	Spinal cord infarction	2	
Symmetrical proximal leg weakness	Vasospasm and cerebral ischemia	1	
Bilateral foot drop	Vasospasm and cerebral ischemia	1	
Quadriparesis or hemiparesis	Brainstem neural injury	22	
Ipsilateral hemiparesis	Compression of cerebral cortex by SAH	1	
Contralateral proximal weakness	Brainstem neural injury	12	
Contralateral leg weakness	Brainstem neural injury	1	
Leg monoparesis	Radiculo- neuropathy	2	

table about the number of studies and patients in each pathogenic mechanism. Considering the high incidence of aneurysmal SAH and motor weakness following aneurysmal SAH, we believe that there is inadequate study on the pathogenic mechanisms of the motor weakness.<sup>1-6</sup> In addition, some studies did not show clear association with motor weakness and evidence for a pathogenic mechanism.<sup>8,13,15</sup> Therefore, further studies on this topic should be encouraged. In particular, studies using DTI, which has a unique advantage in finding lesions at the subcortical level, would be helpful. In addition, further studies on the non-corticospinal tract neural pathways for motor function, such as the corticoreticulospinal tract and corticorubrospinal tract should also be encouraged.

#### ACKNOWLEDGEMENT

This work was supported by the National Research Foundation (NRF) of Korea Grant funded by the Korean Government (MSIP) (2015R1A2A2A01004073).

#### REFERENCES

1. Sarner M, Rose F. Clinical presentation of ruptured intracranial aneurysm. *J Neurol Neurosurg Psychiatry* 1967; 30:67-70.
2. van Gijn J, van Dongen KJ, Vermeulen M, *et al.* Perimesencephalic hemorrhage: a nonaneurysmal and benign form of subarachnoid hemorrhage. *Neurology* 1985; 35:493-7.
3. Ferrante L, Acqui M, Mastronardi L, *et al.* Posterior inferior cerebellar artery (PICA) aneurysm presenting with SAH and contralateral crural monoparesis: a case report. *Surg Neurol* 1992; 38:43-5.
4. Hudgins RJ, Day AL, Quisling RG, *et al.* Aneurysms of the posterior inferior cerebellar artery. A clinical and anatomical analysis. *J Neurosurg* 1983; 58:381-7.
5. Lee KS, Gower DJ, Branch CL, Jr., *et al.* Surgical repair of aneurysms of the posterior inferior cerebellar artery--a clinical series. *Surg Neurol* 1989; 31:85-91.
6. Salzman M, Rigamonti D, Numaguchi Y, *et al.* Aneurysms of the posterior inferior cerebellar artery-vertebral artery complex: variations on a theme. *Neurosurgery* 1990; 27:12-20; discussion 20-1.
7. Yeo SS, Choi BY, Chang CH, *et al.* Evidence of Corticospinal Tract Injury at Midbrain in Patients With Subarachnoid Hemorrhage. *Stroke* 2012; 43:2239-41.
8. Kudo T, Uno T. Ipsilateral hemiparesis caused by subarachnoid hemorrhage in a patient with a ruptured middle cerebral artery aneurysm: a case report. *Neurosurgery* 1984; 15:727-9.

9. Maiuri F, Gangemi M, Corriero G, *et al.* Anterior communicating artery aneurysm presenting with sudden paraplegia. *Surg Neurol* 1986; 25:397-8.
10. Kashiwagi S, Tsuchida E, Shiroyama Y, *et al.* Paraplegia due to a ruptured aneurysm of the distal posterior inferior cerebellar artery. *J Neurol Neurosurg Psychiatry* 1992; 55:836-7.
11. Greene KA, Marciano FF, Dickman CA, *et al.* Anterior communicating artery aneurysm paraparesis syndrome: clinical manifestations and pathologic correlates. *Neurology* 1995; 45:45-50.
12. Kombos T, Meisel HJ, Janz C, *et al.* Paraplegia due to rupture of an anterior communicating artery aneurysm. Consequence of a rare anatomic variant of the A2 segment. *Interv Neuroradiol* 1996; 2:53-7.
13. van de Warrenburg B, Vos P, Merx H, *et al.* Paroxysmal leg weakness and hearing loss in a patient with subarachnoid hemorrhage. *Eur Neurol* 2000; 44:186-7.
14. Endo H, Shimizu H, Tominaga T. Paraparesis associated with ruptured anterior cerebral artery territory aneurysms. *Surg Neurol* 2005; 64:135-9; discussion 39.
15. Johnston JM, Chicoine MR, Dacey RG, Jr., *et al.* Aneurysmal subarachnoid hemorrhage, hydrocephalus, and acute paraparesis. *Neurosurgery* 2008; 63:1119-24; discussion 24.
16. Kostov D, Jankowitz B, Kanaan H, *et al.* Lower extremity monoparesis after aneurysmal subarachnoid hemorrhage. *Clin Neurol Neurosurg* 2010; 112:710-2.
17. Teufack S, Gonzalez F, Rosenwasser R, *et al.* Bilateral footdrop after treatment of an anterior communicating artery aneurysm: a case report and review of the literature. *Neurosurgery* 2011; 68:373-6; discussion 76.
18. Krishna V, Lazaridis C, Ellegala D, *et al.* Spinal cord infarction associated with subarachnoid hemorrhage. *Clin Neurol Neurosurg* 2012; 114:1030-2.
19. Jang SH, Choi BY, Kim SH, *et al.* Injury of the corticoreticular pathway in subarachnoid haemorrhage after rupture of a cerebral artery aneurysm. *J Rehabil Med* 2015; 47:133-7.
20. Logue V. Surgery in spontaneous subarachnoid haemorrhage; operative treatment of aneurysms on the anterior cerebral and anterior communicating artery. *Br Med J* 1956; 1:473-9.
21. Paulson G. Subarachnoid Hemorrhage Associated with Paraplegia. *Dis Nerv Syst* 1963; 24:419-22.
22. Chua CO, Chahboune H, Braun A, *et al.* Consequences of intraventricular hemorrhage in a rabbit pup model. *Stroke* 2009; 40:3369-77.
23. Jang SH. Somatotopic arrangement and location of the corticospinal tract in the brainstem of the human brain. *Yonsei Med J* 2011; 52:553-7.
24. Kwon HG, Hong JH, Jang SH. Anatomic location and somatotopic arrangement of the corticospinal tract at the cerebral peduncle in the human brain. *AJNR Am J Neuroradiol* 2011; 32:2116-9.
25. Yeo SS, Choi BY, Chang CH, *et al.* Periventricular white matter injury by primary intraventricular hemorrhage: a diffusion tensor imaging study. *Eur Neurol* 2011; 66:235-41.
26. Liu Y, Soppi V, Mustonen T, *et al.* Subarachnoid hemorrhage in the subacute stage: elevated apparent diffusion coefficient in normal-appearing brain tissue after treatment. *Radiology* 2007; 242:518-25.
27. Yeo SS, Chang MC, Kwon YH, *et al.* Corticoreticular pathway in the human brain: diffusion tensor tractography study. *Neurosci Lett* 2012; 508:9-12.