

An atypical case of mitochondrial acetoacetyl-CoA thiolase deficiency

Chun-Hui Hu, Qiao-Qiao Qian, Hong-Min Zhu, Dan Sun, Shu-Hua Wu, Ge-fei Wu, Jia-Sheng Hu, Zhi-Sheng Liu

Department of Neurology, Wuhan Children's Hospital, Tongji Medical College, Huazhong University of Science & Technology, Wuhan, China

Abstract

Methylacetoacetyl-CoA thiolase deficiency (T2 deficiency) is a rare congenital and metabolic disease affecting the ketone body and isoleucine metabolism. The typical symptoms are refractory metabolic acidosis, in which large amounts of 2-methyl-3-hydroxybutyryl carnitine, 2-methyl-3-hydroxybutyrate and tiglylglycine are often detected in the blood and urine. We herein describe an atypical case of T2 deficiency with a high level of 3-hydroxybutyrate and a low level of 2-methyl-3-hydroxybutyrate in the urine. Such a case was diagnosed by urinary organic analysis in combination with gene mutation evaluation. Organic acids in the urine were measured using a gas chromatography mass spectrometer and all exons were sequenced via deep sequencing. Molecular biology analysis confirmed the presence of a homozygous mutation in the acetyl-CoA acetyltransferase 1 (ACAT1) gene. The patient received a special diet of deeply hydrolyzed protein milk powder and raw corn starch. She was followed about 6 months. There were no ketoacidotic episodes and hypoglycemia even when she had fever. In conclusion, patients with atypical features of T2 deficiency should also be investigated early. Gas chromatography mass spectrometry and next-generation full exome sequencing may be helpful in diagnosis.

INTRODUCTION

Methylacetoacetyl-CoA thiolase deficiency (OMIM#607809) (MAT deficiency), also known as T2 deficiency, beta-ketothiolase deficiency or 3-ketothiolase deficiency, is a rare disorder of ketone body metabolism and isoleucine catabolism and is characterized by intermittent ketoacidotic episodes of vomiting, hyperventilation and impaired consciousness that are usually precipitated by infections. This disorder was first reported by Daum *et al.* in 1971.¹ To date, more than 100 cases have been reported worldwide. Other clinical symptoms described previously include hyperglycemia, mental retardation, hypotonia, seizure, ataxia, and speech and language delay.²⁻⁴ Large amounts of 2-methyl-3-hydroxybutyryl carnitine, 2-methyl-3-hydroxybutyrate (2M3HB) and tiglylglycine (TG) can be detected in the plasma and urine of patients using tandem mass spectrometry and gas chromatography mass spectrometer analysis. The acetyl-CoA acetyltransferase 1 (ACAT1) gene encodes mitochondrial acetyl-CoA acetyltransferase, a short-chain-length-specific thiolase. Cytosolic acetoacetyl-CoA thiolase is encoded by the ACAT2 gene. T2 deficiency

involves the ACAT1 gene, a gene spanning approximately 27kb and located on chromosome 11q22.3–q23.1. The definitive diagnosis of the disease relies on the analysis of acetoacetyl-CoA thiolase activity using cultured fibroblasts or lymphocytes.

In China, T2 deficiency has been reported using tandem mass spectrometry (MS/MS), or liquid chromatography coupled with tandem mass spectrometry (LC-MS/MS), whilst some reports in China of this disorder were based on the genomic level.⁵⁻⁷ This paper reports an atypical case of T2 deficiency.

CASE REPORT

The patient was an 8-month old Chinese female who were the second child in the family. The patient was delivered at full term via a cesarean section and was admitted into the local hospital with a history of fever, hyperventilation and coma. The history of pregnancy, early growth and development were unremarkable and there was no similar medical history in the family. The patient was well until 8 months of age, when she presented with metabolic acidosis. She had high fever, tachypnoea, lethargy, drowsiness and impaired

Address correspondence to: Dr. Jia-Sheng Hu, Department of Neurology, Wuhan Children's Hospital, Tongji Medical College, Huazhong University of Science & Technology, Wuhan, China. E-mail: chunzhiyue.good@163.com

consciousness for 17 days prior to her admission. The initial laboratory tests indicated the presence of severe metabolic acidosis with an arterial pH of 6.98, PCO_2 of 9 mmHg, blood glucose of 6.9 mmol/L and a bicarbonate level of 10.1 mmol/L. She was intubated and ventilated, given continuous infusion of 5% glucose and sodium bicarbonate. On the fourth day of hospital stay, she was extubated and the blood gas showed no further metabolic acidosis. After regaining consciousness, the patient had normal respiration and her body temperature was normal. The metabolic acidosis has improved and the patient was discharged on the 17th day of hospital stay. However, after one day, the patient had tachypnoea again and her blood gas showed relapse of metabolic acidosis. She was then transferred to our hospital.

On examination, no obvious external features of congenital abnormalities were observed. The mean values of ammonia and plasma lactate concentrations were 42.7 μ mol/L and 1.5 mmol/L, respectively. The blood gas investigation showed an arterial pH of 7.18, a PCO_2 of 27 mmHg and bicarbonate level of 10.1 mmol/L. Investigations for urine ketones were strongly positive. The investigations for sepsis workup, electrolytes, liver enzymes and kidney functions were within the normal range. Brain magnetic resonance imaging (MRI) was normal.

Infusion of sodium bicarbonate was given to raise the arterial pH and the blood bicarbonate. On the second day of hospital stay, blood gas analysis showed arterial pH of 7.25, PCO_2 of 6.3 mmHg, base excess of -19.9, and bicarbonate level of 6.3 mmol/L. The fasting blood glucose was 0.66 mmol/L. Investigations for urine ketones were

still strongly positive. The blood insulin level was normal. Urinary organic analysis conducted using the gas chromatography mass spectrometer showed a large amount of 3-hydroxybutyrate (3HB) and a small amount of 2-methyl-3-hydroxybutyrate (2M) (Figure 1). MS/MS showed no increase of 2-methyl-3-hydroxybutyrate (2MSHB) or 3HB in the blood. The patient was given continuous infusion of sodium bicarbonate. However, the metabolic acidosis was not alleviated until the fifth day of hospital stay. The hypoglycemia improved with continuous infusion of 5% glucose. Meanwhile, the analysis of urinary organic acids revealed that the level of 2M was still elevated (Figure 2).

Genetic studies were then performed. All of the coding regions in the ACAT1 gene were analyzed by a thorough sequencing using an ABI 3730XL sequencing machine. The sequence analysis of the ACAT1 gene identified a homozygous mutation in exon 6: c.547G >A (rs120074141) at chr11: 108009736. This transition resulted in the substitution p.G183R. This mutation has been predicted as harmful, since the amino acid glycine is replaced by arginine and modifies the protein synthesis (Pubmed#1346617; 7173255). We also found that the patient's father and mother were heterozygous for the mutation (Figure 3). succinyl-CoA 3-oxoacid CoA transferase deficiency (SCOT) gene mutations were not found during deep sequencing.

The potassium ion-activated acetoacetyl-CoA thiolase assay was subsequently performed using cultured fibroblasts and the results showed that the acetoacetyl-CoA thiolase activity was absent.

After the diagnosis of T2 deficiency, the patient

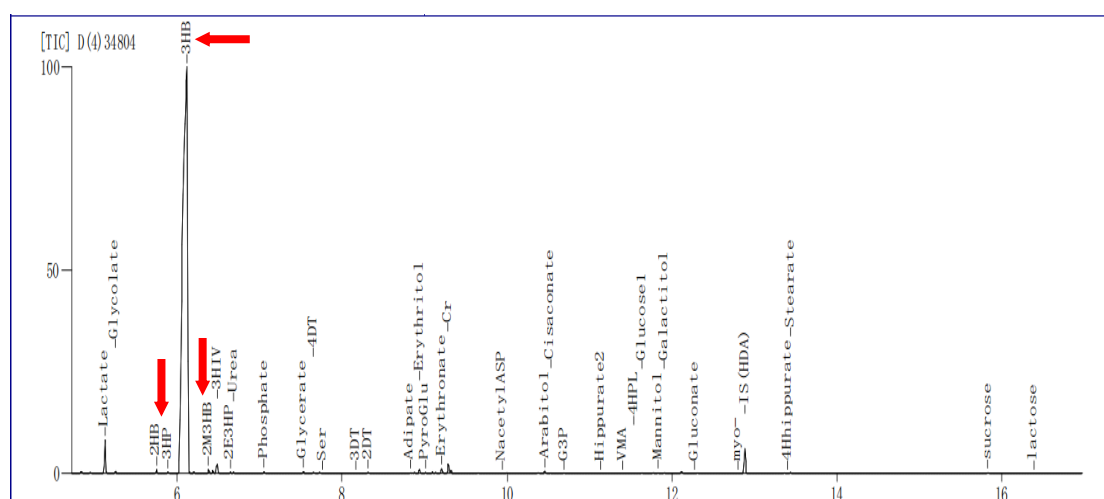


Figure 1. Urinary organic acid profiles of T2 deficiency patient during the acute episode

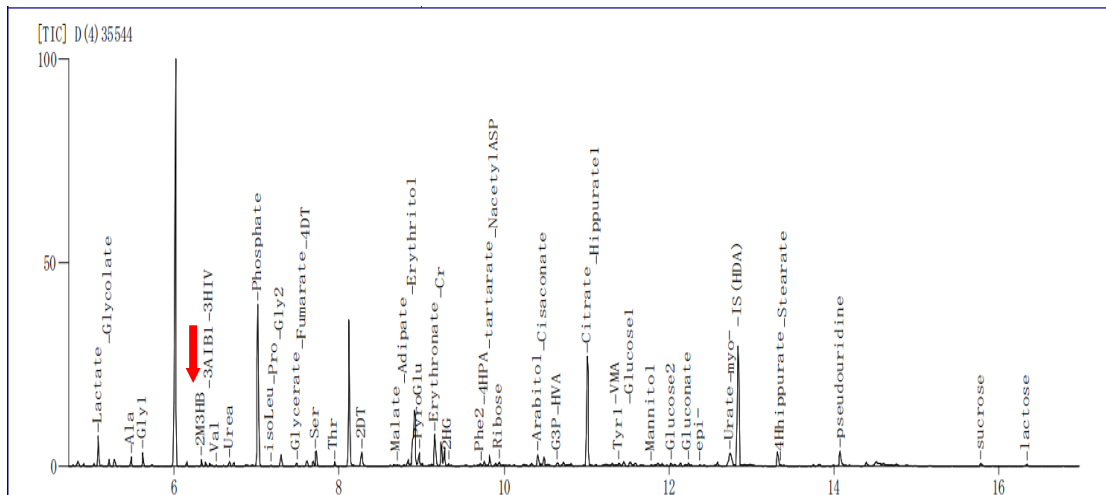
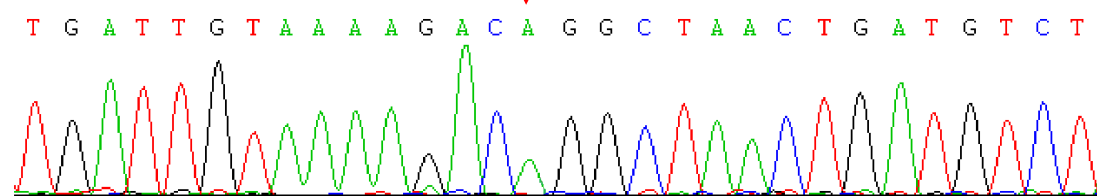


Figure 2. Urinary organic acid profiles of T2 deficiency patient during the asymptomatic period

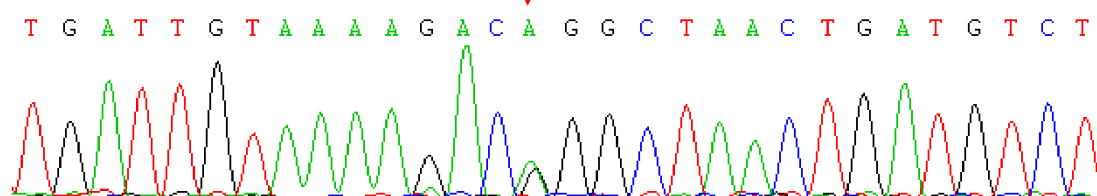
was treated with a special diet of low protein and high calories. She was given the deeply hydrolyzed protein milk powder and raw corn starch. At the same time, L-carnitine was also given to prevent the toxic symptom (20mg/kg intravenously every

day). On fifteenth hospital day, the patient was discharged from hospital well. Home monitoring of blood sugar using a family glucose meter three times a day was advised. The patient was asked to take deeply hydrolyzed protein milk powder and

The patient's coding sequence



The coding sequence of patient's father



The coding sequence of patient's mother

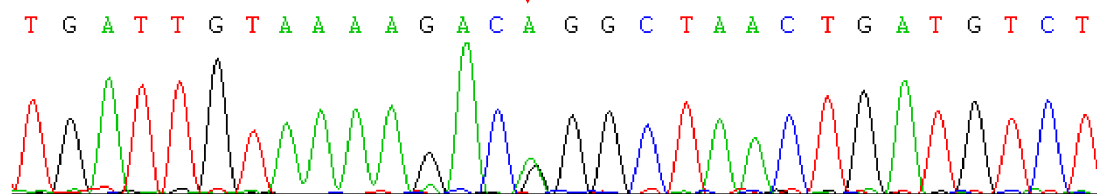


Figure 3. The coding sequence

raw corn starch and avoid excess fat and protein intake. She was treated with L-carnitine (1g orally every day) for 2 months. On follow up, the blood sugar was in normal range. There were no other obvious clinical symptoms. The patient had a fever 3 months after discharging from hospital, but the blood sugar was normal. The patient was advised to continue taking deeply hydrolyzed protein milk powder and raw corn starch. The last follow up was about 6 months after discharging from hospital. There were no intermittent ketoacidotic episodes, hypoglycemia and other symptoms even when she had fever. She was recommended to eat raw corn flour coarse grains cellulose foods, avoid excess fat and protein intake long term.

DISCUSSION

T2 deficiency, or beta-ketothiolase deficiency, is an autosomal recessive disorder that affects the catabolism of isoleucine and ketone bodies, and is usually detected in infants or children. The clinical symptom of T2 deficiency is typically refractory metabolic acidosis, which cannot be overcome by sodium bicarbonate, and is easily triggered by infections. The deficiency of acetoacetyl-CoA thiolase results in a buildup of organic acids such as 2-methylacetoacetate (2MMA), 2M3HB and TG, which is derived from intermediate metabolites of 3HB, as well as acetoacetate, isoleucine and ketone bodies in the ketone metabolic pathway. The routine laboratory tests show large amounts of 2MMA, 2M3HB and TG. Abnormalities in the brain MRI and nuclear magnetic resonance (NMR) spectroscopy of T2 deficiency patients have been reported and can help the clinical diagnosis of this rare disease.⁸⁻⁹

In our patient, the brain MRI was normal. Organic aciduria is a diagnostic hallmark of this disorder. 2M3HB, 2MMA and TG are constantly excreted into the patient's urine and can be detected at very low levels. Generally, the level of 2M3HB is significantly higher than the level of 2MMA, and the latter may sometimes become undetectable. The TG is usually elevated in the urine. However, a small percentage of patients do not excrete TG. 3-hydroxybutyrate (3HB) can also be excreted during an acute and severe ketoacidotic attack, which can cause confusion in interpretation. In our patient, the results of laboratory tests were atypical. The amount of 3HB was significantly higher than that of 2M3HB in the urine. The levels of 2M3HB and 2HB in the urine were slightly increased. Furthermore, 2MMA was absent in the urine. Thus, SCOT

deficiency should be excluded, as large amounts of 3HB were found in the urine and this is not a typical feature of T2 deficiency. In this study, the thorough sequencing helped to distinguish T2 deficiency from SCOT deficiency¹⁰⁻¹¹, where the ACAT1 gene mutation was identified. In this mutation of the ACAT1 gene, the amino acid glycine is replaced by arginine and has been reported by Daum *et al.*¹ Using GC/MS and genomic analysis, we can diagnose T2 deficiency, especially when the ACAT1 gene mutation site has been demonstrated previously.¹²⁻¹⁶ However, the reason for the atypical laboratory results of a low 2M3HB level and a high 3HB level is not clear. At present, MS/MS and LC-MS/MS are established methods used in T2 deficiency to detect subtle variations in blood acylcarnitine. GC/MS is also an increasingly potent way to distinguish minor changes of urinary organic acids during T2 deficiency. For those presenting with atypical manifestations of T2 deficiency, an integrated diagnostic approach is of great importance, particularly for those with small amounts of 2M3HB, 2MMA and TG in the blood and urine that are difficult to be detected by MS/MS, LC-MS/MS and GC-MS.

An early diagnosis and treatment of those atypical cases may be beneficial. In our patient, she received a special diet of deeply hydrolyzed protein milk powder and raw corn starch with low protein and high calories. L-carnitine was also given but not in the acute metabolic acidosis phase. Three months after discharging from the hospital, our patient had an episode of fever, the blood sugar was normal while she was only taking the special diet. So we speculated that a low protein and carbohydrate-rich meals was beneficial. To date, information on treatment of T2 deficiency is mainly based on individual case reports, there was no controlled clinical trial. The clinical severity of T2 deficiency varies among patients. Abdelkreem *et al.*¹⁷ reported 10 Indian Patients with T2 deficiency, 6 patients had a favorable outcome, 1 died, and 3 developed neurodevelopmental sequelae. Nguyen *et al.*¹⁸ reported outcome of 42 T2 deficiency patients with follow up of 10 years. Sixteen of 37 patients had recurrent ketoacidosis. Five patients died: 2 during their first episode of ketoacidosis, 2 during their second episode, and one patient died from the neurological sequelae following the first episode. Nguyen *et al.*¹⁸ emphasized the importance of long-term appropriate management as critical for a favorable outcome. Based on our patient, a low protein and carbohydrate-rich diet

may be beneficial to control symptom and prevent recurrence.

In conclusion, T2 deficiency is a rare disease but good outcome may be possible with early diagnosis and appropriate management.

DISCLOSURE

Conflicts of interest: None

REFERENCES

1. Daum RS, Lamm PH, Mamer OA, *et al.* A “new” disorder of isoleucine catabolism. *Lancet* 1971; 2:1289-90.
2. Kobra SA, Babak S. First report of 3-oxothiolase deficiency in Iran. *Int J Endocrinol Metab* 2014; 12(2):e10 960.
3. Akella RR, Aoyama Y, Mori C, *et al.* Metabolic encephalopathy in beta-ketothiolase deficiency: the first report from India. *Brain Dev* 2014; 36(6):537-40.
4. Arica V, Arica SG, Dag H, *et al.* Beta-ketothiolase deficiency brought with lethargy: case report. *Hum Exp Toxicol* 2011; 30(10):1724-7.
5. Han LS, Ye J, Qiu WJ, *et al.* Selective screening for inborn errors of metabolism on clinical patients using tandem mass spectrometry in China: A four-year report. *J Inherit Metab Dis* 2007; 30:507-14.
6. Peng MZ, Fang Xf, Huang YL, *et al.* Separation and identification of underivatized plasma acylcarnitine isomers using liquid chromatography–tandem mass spectrometry for the differential diagnosis of organic acidemias and fatty acid oxidation defects. *J Chromatogr A* 2013; 1319:97-106.
7. Scolamiero E, Cozzolino C, Albano L, *et al.* Targeted metabolomics in the expanded newborn screening for inborn errors of metabolism. *Mol Biosyst* 2015; 11(6):1525-35.
8. O’Neill ML, Kuo F, Saigal G. MRI of pallidal involvement in beta-ketothiolase deficiency. *J Neuroimaging* 2014; 24:414-7.
9. Law CY, Lam CW, Ching CK, *et al.* NMR-based urinalysis for beta-ketothiolase deficiency. *Clin Chim Acta* 2015; 438(1):222-5.
10. Fukao T, Aoyama Y, Murase K, *et al.* Development of MLPA for human ACAT1 gene and identification of a heterozygous Alu-mediated deletion of exons 3 and 4 in a patient with mitochondrial acetoacetyl-CoA thiolase (T2) deficiency. *Mol Genet Metab* 2013; 110:184-7.
11. Thummler S, Dupont D, Acquaviva C, *et al.* Different clinical presentation in siblings with mitochondrial acetoacetyl-CoA thiolase deficiency and identification of two novel mutations. *Tohoku J Exp Med* 2010; 220:27-31.
12. Fukao T, Maruyama S, Ohura T, *et al.* Three Japanese patients with beta-ketothiolase deficiency who share a mutation, c.431A>C (H144P) in ACAT1: subtle abnormality in urinary organic acid analysis and blood acylcarnitine analysis using tandem mass spectrometry. *JIMD Reports* 2011; 72:107-15.
13. Fukao T, Yamaguchi S, Oni T, *et al.* Identification of three mutant alleles of the gene for mitochondrial acetoacetyl-coenzyme A thiolase. A complete analysis of two generations of a family with 3-ketothiolase deficiency. *J Clin Invest* 2014; 474-9.
14. Estrella J, Wilcken B, Carpenter K, *et al.* Expanded newborn screening in New South Wales: missed cases. *J Inherit Metab Dis* 2014; 37:881-7.
15. Catanzano F, Ombrone D, Di Stefano C, *et al.* The first case of mitochondrial acetoacetyl-CoA thiolase deficiency identified by expanded newborn metabolic screening in Italy: the importance of an integrated diagnostic approach. *J Inherit Metab Dis* 2010; 33:S91-S94.
16. Sarafoglou K, Matern D, Redlinger-Grosse K, *et al.* Siblings with mitochondrial acetoacetyl-CoA thiolase deficiency not identified by newborn screening. *Pediatrics* 2011; 128:e246.
17. Abdelkreem E, Akella RR, Dave U, *et al.* Clinical and mutational characterizations of ten Indian patients with beta-ketothiolase deficiency. *JIMD Rep* 2016; (Epub ahead of print Dec 8).
18. Nguyen KN, Abdelkreem E, Colombo R, *et al.* Characterization and outcome of 41 patients with beta-ketothiolase deficiency: 10 years’ experience of a medical center in northern Vietnam. *J Inherit Metab Dis* 2017; 40(3):395-401.